

## Study of the effective traditional role of *Cuscuta Reflexa* Roxb. in Alleviating inflammation and hepatotoxicity in Wistar Rats

Nilanjan Adhikari, Sumit Dutta, Saroj Singhmura\*  
Dr. B.C. Roy College of Pharmacy & AHS, Durgapur, West Bengal, India.  
Corresponding Author: Saroj Singhmura.

---

### ABSTRACT:

NSAIDs (Non-steroidal anti-inflammatory drugs) which are mostly used for analgesic, antipyretic and anti-inflammatory actions and are being frequently prescribed by physicians but in terms of adverse effects on its use, it sets a drawback due to many reported cases of hepatotoxicity. As an alternative to the conventional, *Cuscuta Reflexa* Roxb. a traditional herb used by many indigenous people for various ailments was selected to study for its folkloric claims as anti-inflammatory and hepatoprotective action. Acute toxicity of the aqueous extract of *Cuscuta Reflexa* Roxb. (AEER) was found to be safe at 2000mg/kg. The effectiveness in suppressing the inflammation due to carrageenan was also observed in a dose-dependent manner in the treatment groups. At the same time while hepatoprotective role was also observed as serum level various biochemical markers of liver injury was found to be suppressed and histopathology reports also seem to support the results. Thus in the present study it was concluded that our choice of herbs was successfully able to establish the traditional claims and open the door for further possibilities to explore this magical herb at molecular level to reveal the important moiety responsible for its claims.

**KEYWORDS:** NSAIDs, hepatoprotective, anti-inflammatory, *Cuscuta reflexa* Roxb.

---

Date of Submission: 08-08-2020

Date of acceptance: 21-08-2020

---

### I. INTRODUCTION

One of the groups of drug which are frequently prescribed by physician is NSAIDs. But if we follow the history of NSAIDs drugs from the past, we will notice several NSAIDs come under the radar of hepatotoxicity as major adverse effects. As per a French study, NSAIDs was considered to be the 4<sup>th</sup> leading cause of Drug Induced Liver Injury (DILI).<sup>[1]</sup> From earlier reports it has been found that due to DILI, many NSAIDs have been resulted for minimize use with cautions and even withdrawal from the market. Various such include like Bromfenac<sup>[2,3]</sup>, Ibuprofen<sup>[4,5]</sup>, Benoxaprofen,<sup>[4,5]</sup> Nimesulide<sup>[6,7,8]</sup>, Diclofenac<sup>[9,10,11]</sup> and Lumiracoxib<sup>[12]</sup>.

Thus, there is always a tenacity of shifting to an alternative way in which therapeutic effectiveness will not be compromised with the of treatment procedure. This enlightened the path towards the use of ethnomedicines in the treatment of this type of condition. Since ancient people was accustomed with the Ethnomedicines. The rich history of Ethnomedicines has given a wing to budding researcher to extract the medicinal value from vast natural resources<sup>[13,14]</sup> So, Scope of the study focus on the treatment with minimising the limitations like ADR, Cost in conventional drugs, and quest of more potent substances from Natural resources having both anti-inflammatory and hepatoprotective activity.<sup>[15]</sup>

Search of Scientific database was done using search engine like science Direct and PubMed central database using the search terms, traditional plants, hepatoprotective, and anti-inflammatory as keywords and for a period upto November 2018. Many traditional plants were accounted in the list out of which as per the requirements and easy availability of the sources a very promising and effective in terms of their traditional claims has been selected for the present study. *Cuscuta reflexa* Roxb. (known as Dodder plants, Alak pui, Swarnalata, Akashbel, Aftimoon etc) is the choice of plant and was collected from the Purulia district in the month of October 2018. It is a yellowish green leafless parasite belonging from the family of Convolvulaceae, thread like twinning herb cover to the host plant; Distributed in India (Gujrat, Haryana, Madhya Pradesh, West Bengal, Odisha and Sikkim), Afghanistan, Bangladesh, Bhutan.<sup>[16]</sup>



Figure no. 1 *Cuscuta Reflexa* Roxb.

## II. MATERIALS AND METHOD

**Preparation of extract :-** The plant 'Alakpui' from Purulia district was collected in the month of May-2018, and was authenticated by Botanical Survey of India, Central National Herbarium, Howrah (West Bengal) with a voucher specimen no. AG-01. After collection it is cut into small pieces and dried in shade. Then powdered crude stems of CR packed (65gm) in a thimble, loaded in the extraction chamber of the Soxhlet apparatus. Boiling flask will first run with petroleum ether (60°C-80°C) for defatting, after that chloroform (60°C-62°C) was run to remove chlorophyll or other pigments. Then was run with ethylacetate. Following on water and methanol (90:10), a aqueous solvent will be running for the extraction and all the extractants were collected.

The solvents were then separated out from the collected extractant by using vacuum rotary evaporator and a semisolid mass was obtained and kept for further investigation.

**Materials:** - All the Chemicals like Pet. Ether, ethyl acetate, chloroform, methanol; and drugs like Silymarin, Paracetamol, Diclofenac sodium was taken as laboratory standard. Instruments like Rota evaporator, UV spectrophotometer, Lyophilizer, Digital Plethysmometer was used.

**Animal Used:-** 80 Wistar Males Rats about 150-200gm body weight and acclimatized before uses in institution premises by maintaining proper room temp (18-29°C), 30-70% RH and food and water ad libitum.<sup>[17]</sup> All animal experiments were performed as per CPCSEA guidelines and prior permission also taken from IAEC. [IAEC/BCRCP/1348]

**Acute Toxicity:** Acute toxicity was done as per OECD guideline 425, NOAEL was observed at 2000 mg/kg

**Anti-inflammatory Study:** Anti-inflammatory activity was done by Carrageenan induced paw edema. 36 Animals was divided into six groups (Normal Control, Vehicle Control, Toxic Control, Standard and Test low, medium & high dose), containing 5 animals in each. Paw edema was induced in a right hind paw of each rat by intraplantar injection of 100 µL of 1% (suspension in saline) carrageenan. Aqueous extract (150, 200 and 250 mg/kg) orally and Diclofenac Sodium (25 mg/kg) were intraperitoneally administered 30 min before the carrageenan injection. Successively at a interval of one hour three reading was taken. Volume of paw edema compare with control vs test group data for assessing the degree of inflammation.<sup>[18]</sup>

**Hepatoprotective Study:** -36 Animals was divided into six groups (Normal Control, Vehicle Control, Toxic Control, Standard and Test low, medium & high dose), containing 5 animals in each. Normal & Toxic Control groups treated with Normal saline (1mg/kg p.o.) and 0.5% CMC solution to Vehicle Control for 7 day. Standard group was treated with Silymarin (100mg/kg p.o.) single time per day. Test groups treated with 150, 200 and 250 mg/kg oral dose of aqueous extract at a single time per day. Except Normal & Vehicle control group, Hepatotoxicity conducted with single dosage of PCM at 2 gm/kg on the 5<sup>th</sup> day of the study protocol orally, On the 7<sup>th</sup> day after 48 h of pharmacological treatments, blood was withdrawn by retro orbital puncture for the estimation of biochemical parameters (AST, ALT, ALP). After that animals were sacrificed by cervical dislocation and the liver was collected, washed and used for histopathological studies.<sup>[19]</sup> Plasma levels of aspartate aminotransferase (AST), alanine aminotransferase (ALT) and alkaline phosphatase (ALP) were

measured as indicators of liver function parameters using commercial diagnostic assay kits from ARKRAY Healthcare Pvt. Ltd. (Surat, India) following the instructions of the manufacturer.

**Histopathological Study:** -After sacrificed of animal by cervical dislocation, the liver was dissected out washed properly and taken, fixed in 10% neutral-buffered formaldehyde solution. Each sample was embedded in paraffin wax, sectioned at 5 μm and stained with H and E. A representative area was selected for qualitative light microscopic analysis of the inflammatory cellular response with a ×45 objective.<sup>[20]</sup>

**Statistical Analysis:**

All the data obtained from this study were expressed as mean ±SEM, using Primer Software and MS Office 2013

**III. RESULTS & OBSERVATIONS:**

**Anti-inflammatory study:**

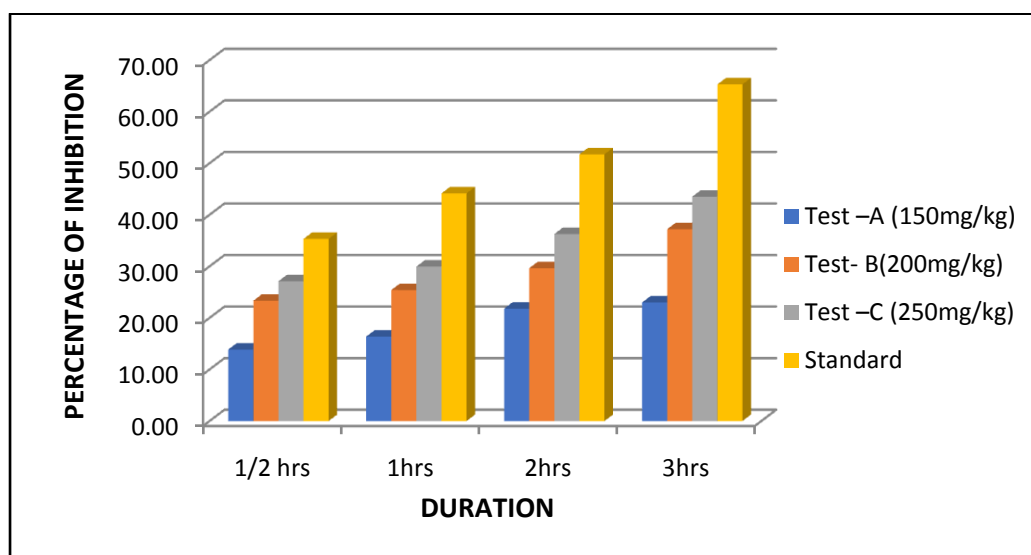
**Observation Table-1.1 → Time table for assessment of Anti-Inflammatory**

GROUPS	Before	0 hr	1/2hr	+1 hrs	+2hrs	+3hrs
Normal Control	0.81±0.007	0.86±0.007	1.49±0.009	1.70±0.007	1.78±0.017	1.73±0.015
Vehicle Control	0.80±0.013	0.85±0.013	1.45±0.011	1.69±0.013	1.77±0.015	1.732±0.017
Test -A (150mg/kg)	0.76±0.09	0.80±0.014	1.35±0.09	1.50±0.018	1.52±0.026	1.48±0.045
Test- B(200mg/kg)	0.79±0.021	0.92±0.013	1.41±0.006	1.55±0.0108	1.66±0.011	1.56±0.035
Test (250 mg/kg)	0.80±0.015	0.93±0.015	1.31±0.015	1.5±0.015	1.63±0.015	1.59±0.015
Standard	0.80±0.011	0.87±0.011	1.28±0.011	1.43±0.012	1.47±0.012	1.34±0.011

\*\*All values are reported as mean ± SEM

**Observation Table 1.2 → Percentage of Inhibition in duration of times for assessment Anti-Inflammatory activity**

GROUPS	PERCENTAGE OF INHIBITION			
	1/2 hrs	1hrs	2hrs	3hrs
Test -A (150mg/kg)	13.88	16.39	21.81	23.01
Test- B(200mg/kg)	23.34	25.42	29.65	37.22
Test -C (250mg/kg)	27.13	29.97	36.28	43.53
Standard	35.33	44.16	51.74	65.30



**FIG I:** Percentage of Inhibition of AECR (150,200 & 250 mg/kg) in respect of Standard (Diclofenac Sodium) as different interval of time respectively.

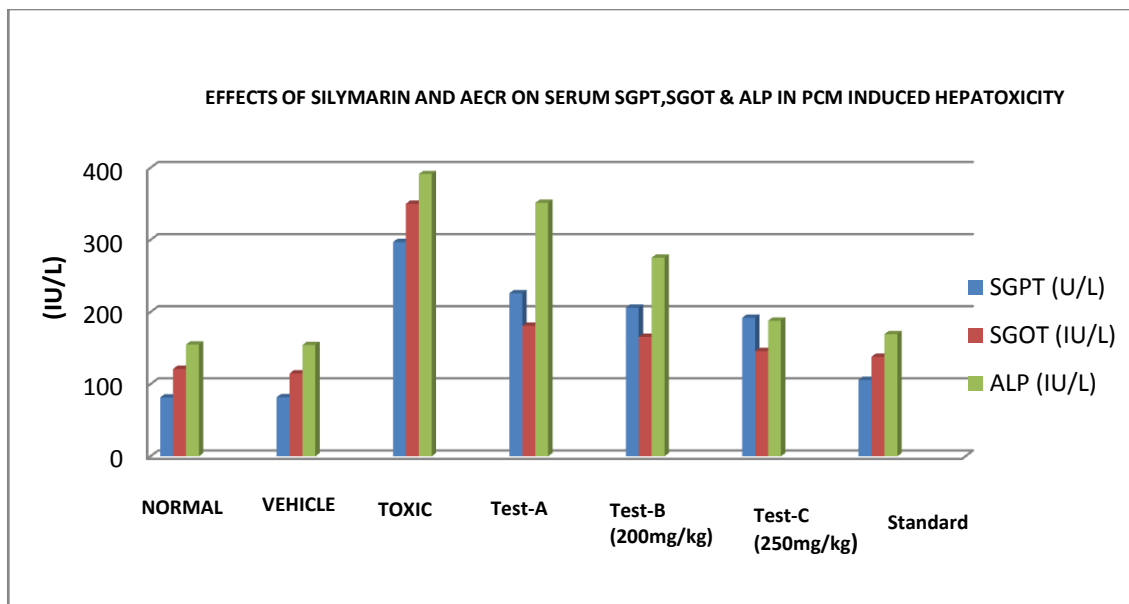
**Hepatoprotective Study:**

**Observation Table-2: Assessment of Bio marker (SGPT, SGOT, ALP respectively)**

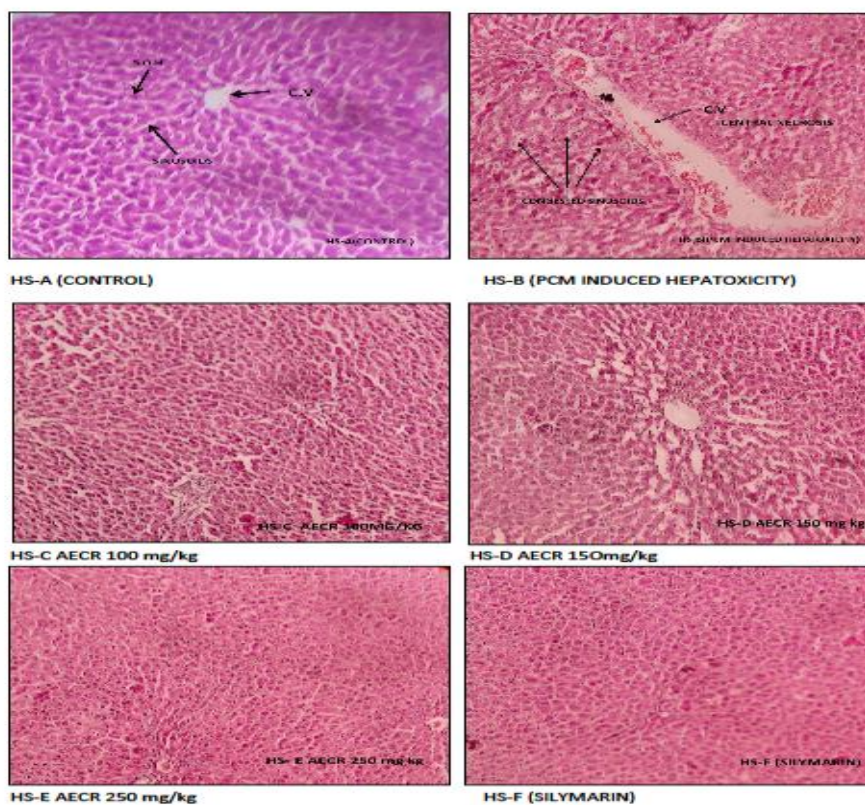
Group Code	Group Category	SGPT	SGOT	ALP
		(IU/L)	(IU/L)	(IU/L)
Group A	Normal Control	81.6±1.2	121.2±1.39	155±1.8
Group B	Vehicle Control	81.8±1.98	114.8±4.48	154.4±1.8

Group C	Toxic Control	297±3.08	350.2±6.11	391.4±9.9
Group D	Test-I (150mg/kg)	226.16±2.45	181±3.5	351.4±2.9
	Test-II (200mg/kg)	206±2.45	165.6±3.6	275.4±1.02
	Test-III (250mg/kg)	192.12±3.27	146±3.5	188±0.8
Group E	Standard	106±4.9	138±1	169.4±2.1

\*\*All values are reported as mean ± SEM



**FIG II:** Effects of Silymarin and AECR on serum ALT, AST & ALP in PCM induced hepatotoxicity



**FIG III:** Histopathological Slides [Control, Toxic, Standard, Test -150,200 & 250 mg/kg Groups]



#### IV. DISCUSSION:

**Anti-inflammatory Activity:** - The ACER showed a dose dependent % inhibition of carrageenan induced rat paw edema from ½ hours to next 3 hour after the administration of the drug compared to the Control group. (Table No- 1.1 &1.2, Figure No- I)

**Hepatoprotective Activity:** - Increased Serum hepatic enzymes level AST, ALT, ALP as compared to the control groups and from the figure- it is cleared that treated groups show dose dependent effective in suppressing the damage caused by PCM.

**Histopathology Study:** - On histopathological investigation of the effects of three different doses, it was observed that the normal architecture of the hepatocytes was being found to be maintained in case of the normal group, with proper architecture of hepatocytes, sheets of hepatocytes (S.O.H), sinusoids and sinusoidal spaces and distinct central vein which was clearly visible. Whereas PCM induced hepatotoxicity, shows presence of centralized necrosis & degeneration patches sinusoids. Significantly observation in the treated groups i.e., HS-C AECR 150 mg/kg, HS-D AECR 200mg/kg, HS-E AECR 250 mg/kg was observed in effective protection and reduction of hepatic lesions as induced by the PCM similar to the group that was treated with the standard Drug silymarin.

#### V. CONCLUSION:

The genus *Cuscuta*, which belong to *Cuscutaceae* family, include more than 200 species. All of them has highly in versatile chemical constituents and was used traditionally for many ailments. Our species of the present study being one of the notable one among those, whose detail study to establish various traditional chain are still need to be unfold.

Thus, in our present study with our objectives AECR was investigated for an alternative to curb the crisis of NSAIDs, as anti-inflammatory & hepatoprotective. As per the result obtained, it's clearly shows our investigated herb established the folkloric claims .Further molecular investigation is needed to unfold active moiety responsible for the Human benefits.

#### REFERENCES:

- [1]. Paul A Schmeltzer, Drug-Induced Liver Injury Due to Nonsteroidal Anti-inflammatory Drugs. *Current Hepatology Reports*. 2019, 18:P.294-299
- [2]. Gholivand MB, Nasrabadi MR, Batooli H, Ebrahimabadi AH, Chemical composition and antioxidant activities of essential oil and methanol extracts of *Psammogeton canescens*. *Food and Chemical Toxicology*, 2010, 48:P. 24-28.
- [3]. Fernando Bessone, Non-steroidal anti-inflammatory drugs: What is the actual risk of liver damage? *World J Gastroenterol*. 2010, 16(45):P. 5651-5661
- [4]. Goudie BM, Birnie GF, Watkinson G., Jaundice associated with the use of Benoxaprofen. *Lancet* 1982; 1(8278):959.
- [5]. Taggart HM, Allerdice JM. Fatal cholestatic jaundice in elderly patients taking benoxaprofen. *BMJ* 1982; 284:1783.
- [6]. Giuliano F, Ferraz JG, Pereira R, de Nucci G, Warner TD, Cyclooxygenase selectivity of non-steroidal anti-inflammatory drugs in humans: ex vivo evaluation. *European Journal of Pharmacology*. 2001, 426: P.95-103
- [7]. Chatterjee M, Sil PC, Protective role of *Phyllanthus niruri* against nimesulide induced hepatic damage. *Indian Journal of Clinical Biochemistry*. 2007, 22: P. 109-116
- [8]. Lucena MI, Camargo R, Andrade RJ, Perez-Sanchez CJ, Sanchez De La Cuesta F, Comparison of two clinical scales for causality assessment in hepatotoxicity. *Hepatology* .2001, 33:P. 123-130
- [9]. Tang W, Stearns RA, Wang RW, Chiu SH, Baillie TA , Roles of human hepatic cytochrome P450s2C9 and 3A4 in the metabolic activation of diclofenac. *Chemical Research in Toxicology*. 1999, 12:P.192-199.
- [10]. Purcell P, Henry D, Melville G, Diclofenac hepatitis. *Gut* 1991, 32:P. 1381-1385
- [11]. Banks AT, Zimmerman HJ, Ishak KG, Harter JG , Diclofenac-associated hepatotoxicity: analysis of 180 cases reported to the food and drug administration as adverse reactions. *Hepatology*. 1995, 22: P.820-827.
- [12]. Paul A Schmeltzer, Drug-Induced Liver Injury Due to Nonsteroidal Anti-inflammatory Drugs, *Current Hepatology Reports* (2019) 18:294-299
- [13]. Stepp JR, Moerman DE, The importance of weeds in ethnopharmacology. *Journal of ethnopharmacology*. 2001, 75(1):P.19-23.
- [14]. Farnsworth NR. Ethnopharmacology and drug development. *Ethnobotany and the search for new drugs*. 1994, 1(185):P.42-51.
- [15]. Kala CP, Ethnomedicinal botany of the Apatani in the Eastern Himalayan region of India. *Journal of Ethnobiology and Ethnomedicine*. 2005, 1(1):P.11.
- [16]. Vijikumar S. *Cuscuta reflexa* Roxb—A wonderful miracle plant in ethnomedicine. *Indian J. Nat. Sci. Int. Bimon*. 2011;P.976:997.
- [17]. Committee for the Purpose of Control and Supervision on Experiments on Animals. CPCSEA Guidelines for laboratory animal facility. *Indian J. Pharmacol.* 2003;35(4).
- [18]. Mansouri MT, Hemmati AA, Naghizadeh B, Mard SA, Rezaie A, Ghorbanzadeh B. A study of the mechanisms underlying the anti-inflammatory effect of ellagic acid in carrageenan-induced paw edema in rats. *Indian Journal of Pharmacology*. 2015, 47(3):P.292.
- [19]. Mishra G, Khosa RL, Singh P, Jha KK. Hepatoprotective potential of ethanolic extract of *Pandanus odoratissimus* root against paracetamol-induced hepatotoxicity in rats. *Journal of Pharmacy & Bioallied Sciences*. 2015, 7(1):P.45.
- [20]. Quirke P, Dixon MF. The prediction of local recurrence in rectal adenocarcinoma by histopathological examination. *International journal of colorectal disease*. 1988, 1;3(2):P.127-31.

Saroj Singhmura. "Study of the effective traditional role of *Cuscuta Reflexa* Roxb.in Alleviating inflammation and hepatotoxicity in Wistar Rats." *International Journal of Pharmaceutical Science Invention*, vol. 09(6), 2020, pp 01-05. Journal DOI- 10.35629/6718