

Atypical Intestinal Malrotation and Volvulus in Adult:

¹Ikhwan SM, ²Mazwan M, ³Amir KS, ⁴MI Ibariyah, ⁵Andee Z, ⁶Z.Zaidi,
⁷Saravanan K

^{1,2,3,4,5,6}Department of Surgery, School of Medical Sciences, Universiti Sains Malaysia Health Campus, Kelantan.

ABSTRACT: Intestinal malrotation occurs in 1 of every 500 live birth in the United States. Up to 40% of patient with malrotation shows sign of disease within the first week of life. By 1 month of age, 50 to 60% are diagnosed. Seventy-five to 90% of patient are diagnosed by age 1. The remaining cases are diagnosed after age 1 and into adulthood. Here we report a case of a 45-year-old man who presented with acute abdomen secondary intestinal obstruction which is occur in 2 days duration. Abdominal

x ray showed dilated small bowel. Abdomen was tender and guarding. Emergency exploratory laparotomy was done and noted a closed loop small bowel obstruction secondary to small bowel volvulus. During the attempt to relieve the volvulus, there was intestinal malrotation which the transverse colon located posterior to the small bowel, the caecum was high up from right iliac fossa. Unfortunately at postoperative day 2 patient developed abdominal compartment syndrome, then proceeded with second laparotomy. Intraoperative finding was distal portion of small bowel gangrene. Bowel resection was done with remnant of viable small bowel left around 130cm from the duodenal junction. We also created double barrel ileostomy. Patient was nursed in ICU for 17 days. He developed a complication of short bowel syndrome in which he had total daily ileostomy output of 800 to 1500 mls per day. Fortunately the ileostomy loss reduced to less than 500 ml after 6 weeks and reversal of ileostomy was successfully performed 2 months later.

I. CASE SUMMARY

A 45-year-old Malay man presented to us with sudden onset of generalized abdominal pain for 2 days which was sharp in nature. The pain was not relieved by analgesia. He had bilious vomiting. He had no bowel motion or flatus for 2 days.

Examination revealed generalized abdominal distention and tenderness. Bowel sound was absent, and digital rectal examination revealed absence of stool or mass. Initial Ryles tube flow was 20cc bile. Full blood count showed leucocytosis while arterial blood gases showed metabolic acidosis. Plain abdominal x ray showed dilated small bowel.

Decision was made immediately for emergency exploratory laparotomy in view of patient developing peritonitis. Intraoperative finding was small bowel volvulus with closed loop intestinal obstruction. Location of the Caecum was high at the right hypochondrium and the transverse colon located at the posterior of the small bowel (jejunum and ileum). The volvulus occurred at the DJ junction. There was 440 degree rotation of volvulus. The small bowel colour were dusky. The volvulus was untwisted and bowel resuscitation was done. We proceeded with limited right hemicolectomy in view of remaining 180 longitudinal rotation of ileum at the terminal ileum region.

Postoperatively the patient was nursed in ICU. At postoperative day 2, he developed abdominal compartment syndrome with persistent metabolic acidosis. Second emergency laparotomy was done. Resection of gangrenous small bowel was done and double barrel ileostomy was done. Remnant small bowel left were 130cm from duodenal junction. He was then transfer to ICU for intensive care management. He progressed well, extubated at postoperative day 9 relaparotomy and started with enteral feeding via ryle tube. He was transferred to general ward after 17 of ICU care. He developed a complication of short bowel syndrome in which he had total daily ileostomy output of 800 to 1500 mls per day. Fortunately the ileostomy loss reduced to less than 500 ml after 6 weeks and reversal of ileostomy was successfully performed 2 months later.

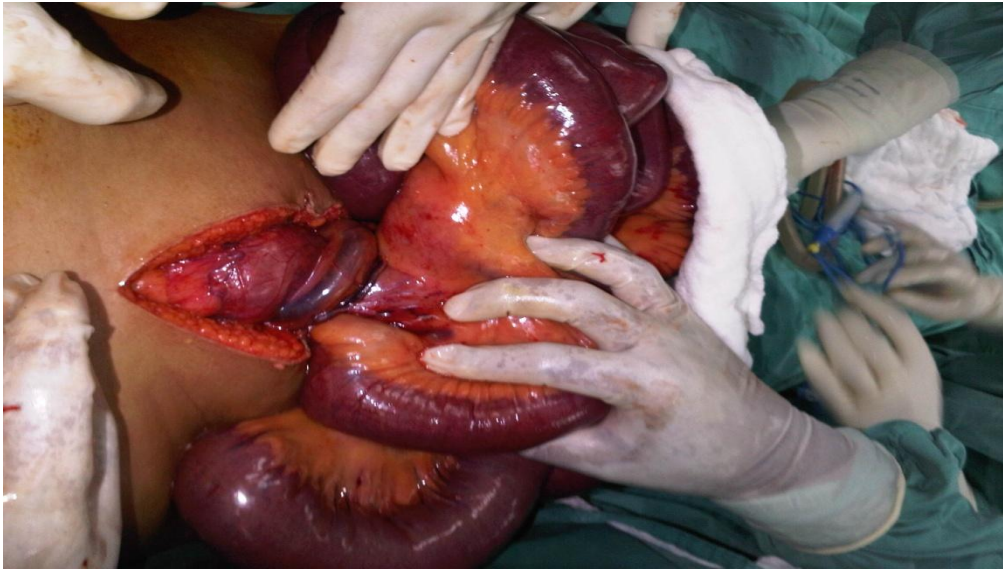


Figure 1 :Volvulus > 360 rotation at the DJ junction.

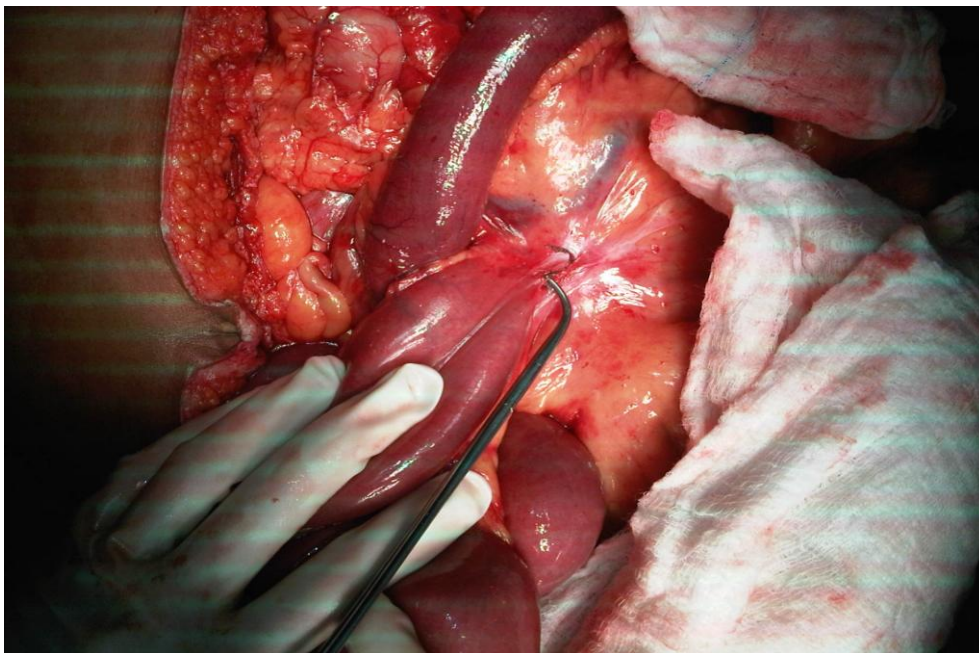


Figure 2: DJ junction after untwisted the volvulus. Noted that the transverse colon posterior location of small bowel.(not in picture).

II. DISCUSSION

Intestinal malrotation is a defect that occurs at the 10th week of gestation. During this stage of development, the intestinal normally migrate back into the abdominal cavity following a brief period where they are temporarily located at the base of the umbilical cord. As the intestine returns to the abdomen, it makes 2 rotations and becomes fixed into its normal position, with the small bowel centrally located in the abdomen and the colon (large intestine) draping around the top and sides of the small intestine. When rotation is incomplete and intestinal fixation does not occur, this created a defect known as intestinal malrotation. With intestinal malrotation, the large intestine is located to the left of the abdomen, while small intestine is on the right of abdomen. The caecum (beginning of large intestine) and appendix, which are normally attached to the right lower abdomen, are unattached and located in the upper abdomen. In many cases, abnormal tissue referred to as Ladd's band attaches the caecum to the duodenum (beginning of small intestine) and may created blockage in the duodenum.

In patient with malrotation, the blood supply to the intestine is channeled through a very narrow supportive structure (mesentery). Since the intestine is not properly fixated, the bowel may twist on its own blood supply; this condition is termed volvulus. When volvulus involves the entire small bowel, it is referred to as mid gut volvulus. This can result in the loss of most of the intestine. In some case, it may also result in death. Few other acute and chronic signs of disease are related to intestinal malrotation and lack of fixation. These include chronic abdominal pain, malabsorption and malnutrition and subsequent growth disturbances. The incidence of intestinal malrotation occurs in 1 of every 500 live birth. Up to 40% of patients with malrotation show signs of disease within the first week of life. By 1 month of age, 50-60% are diagnosed. Seventy-five to 90% of patients are diagnosed by age 1. The remaining cases are diagnosed after age 1 and into adulthood. Our case report is the most rare that occur in adult age. Maybe this is the first case report occur at this age. While more boys exhibit symptoms during the first month of life, malrotation occurs equally in boys and girls. Up to 70% of children with intestinal malrotation also have another defect that is present at birth (congenital), including:

- Abdominal wall defects and digestive system abnormalities, including gastrochisis, omphalocolle, congenital diaphragmatic hernia, intestinal atresia, Hirschsprung's disease, GERD, Intussusception and anorectal malformation.
- Heart defects.
- Liver and spleen abnormality.

In some people with malrotation, symptoms never occur and diagnosis is never made. In others, symptom may develop at any age.

When the intestine is obstructed by Ladd's band or when the blood supply is twisted, symptom may include:

- Vomiting bile (greenish-yellow digestive fluid)
- Abdominal pain
- Abdominal swelling
- Rapid heart beat
- Shock
- Rapid breathing
- Bloody bowel movement.

When medical history and physical examination indicate a suspicious of malrotation and volvulus, patient must undergo various blood test and diagnostic imaging studies to evaluate the position of the intestine and to determine whether there is intestinal blockage or twisting. These tests include:

1. Abdominal X ray; this may reveal intestinal obstruction
2. Barium swallow; this procedure examines the small bowel for abnormalities and established the position of jejunum in relation to the spine and stomach. A chalky fluid called barium is swallowed or placed down a nasogastric tube which goes from the nose into the stomach.
3. Barium enema; X-rays may show that large intestine is not normal position.
4. Abdominal ultrasound; is a diagnostic test that uses invisible electromagnetic energy beams to produce images of internal organs. US are used to view internal organs as they function and to assess blood flow through various vessels.

Malrotation of the intestine is usually asymptomatic until the intestine become twisted or obstructed by Ladd's bands. Since all the functional intestine can die with a volvulus, this is considered life threatening. Patient must resuscitated with IV fluid to prevent dehydrated, and antibiotic administered to prevent infection. A nasogastric tube is placed to prevent gas build up in stomach.

Surgical repair is performed as soon as possible. The bowel is untwisted and checked carefully for damage. Ideally, circulation to the intestine is restored after it is untwisted, allowing it to regain its pink coloration. If the intestine is healthy, an operation called Ladd's procedure is performed to repair the malrotation. Since the appendix is not in the correct location, and it would be difficult to diagnose a future appendicitis, it's usually removed at same time.

If the blood supply to the intestine remains in question after untwisting, another operation is usually performed within 24 – 48H to re-evaluate it and determine the extent of bowel necrosis. If it appears that a section of intestine is severely damage beyond recovery, this damage portion is removed. This sometimes necessities surgically creating a small bowel stoma. This stoma allowed the small bowel to heal. After several weeks, an reversal stoma done to restore bowel position intraperitoneal cavity.

When surgical repair is performed before intestinal damage occurs, there are generally no long term problems. However, removal of large portion of intestine can severely affect the digestive process. With this

operation, the normal intestinal process of absorbing nutrient and fluids will be impaired. Nutrition may need to supplement with long term intravenous high calorie solution. This type of supplemental feeding is referred to as total parenteral nutrition (TPN). If the bowel does not recover its function and long TPN may consider. Mortality rates substantially increase with the presence of necrotic bowel at surgery and presence of other co-existing abnormalities. However, they decrease with age, with the average mortality in infant varying from 5-10%.

CONCLUSION

This case report may be the first had been reported about the intestinal malrotation and volvulus in adult generally and age 40' specifically in Malaysia. The total management depend to the assessment during presentation. Surgery is the definite management for this case. With contributing with multidisciplinary department (surgery, anaesth, dietitian, physiotherapy) the acute condition of patient will resolved and recovery well.

REFERENCES

- [1.] Ladd WE. "Surgical Disease of Alimentary Tract In Infants". NEJM 1936;215: 705-708. October 15.
- [2.] Dietz DW, Walsh RM, Grunfest-Broniatowski S, Lavery IC, Fazio VW, Vogt DP
- [3.] "Intestinal Malrotation: a Rare But Important cause Of Bowel Obstruction in Adult". Dis.Colon Rectum 45(10): 1381-1386.
- [4.] Stalker HJ, Chitayat D. "Familial Intestinal Malrotation With Midgut Volvulus and Facial Anomalies: a Disorder Involving a Gene Controlling the Normal Gut Rotation.". Am.J.Med.Genet. 44(1): 46-47.
- [5.] Yeh WC, Wang HP, Chen C, Wang HH, Wu MS, Lin JT " Perioperative sosnographic diagnosis of midgut malrotation with valvulus in adults: the whirlpool sign."(1999). Journal of Clinical Ultrasound 27(5): 279-283.