

MRI Contrast Agents: Developments, Challenges, and Future Trends

Sami S. Alshowiman^{1*}, Ayman K. Alswailem¹, Omar A. Almohizy²,
Abdurrahman A. Alfawaz^{2*}, Abdulaziz A. Ibn Alshaikh²

This work was carried out in collaboration between all authors. Authors SSS and AKS Designed the study, wrote the protocol and wrote the first draft of the manuscript. Authors OAM, AAA and AAS managed the literature searches. All authors read and approved the final manuscript.

1-Prince Sultan Cardiac center, Saudi Arabia

2—Medical Services of Defense, Saudi Arabia

ABSTRACT: Contrast agents in medicine are chemical materials used to improve tissue and fluid contrast in the body during medical imaging. It is mainly used in improving the visibility of blood vessels and the gastrointestinal tract. Some types of contrast materials are used in a medical imaging examination and can be classified according to the imaging technique used. The first contrast agent dates back to 1988 which is called gadopentetate dimeglumine (Magnevist[®]) and was allocated for Magnetic Resonance Imaging (MRI). Then, it has become available in clinical use. Afterwards, many studies have examined the capability of MRI contrast agents to be used in diagnostic imaging in all parts of the body including the skin, the central nervous system, heart and circulation, breast, lungs, musculoskeletal and lymphatic systems, and even the gastrointestinal tract. Nowadays, MRI contrast agents are widely used in clinical practice and has expanded beyond the initial expectations to be a key tool in disease diagnosis around the world. Contrast-Enhanced (CE) MRI keeps in development and new technologies have emerged and new agents were introduced, with great opportunity being provided to ensure better imaging and patient management practices. Also, new clinical challenges were associated with the progress in CE-MRI. This paper aims to overview the historical development of MRI and contrast materials in order to shed light on the clinical development of CE-MRI. Also, the paper overviews the contemporary perspectives and clinical challenges associated with CE-MRI with the provision of significant future trends.

Research Questions

This paper attempts to answer the following questions:

1. What are the historical development stages that CE-MRI has undergone?
2. What are the current trends of CE-MRI?
3. What are the clinical challenges associated with CE-MRI development?
4. What are the future perspectives of CE-MRI?

Date of Submission: 19-04-2018

Date of acceptance: 04-05-2018

I INTRODUCTION

Magnetic Resonance Imaging (MRI) is one of the most advanced means of looking into the living human body. One of the advantages of this technique is that it does not use radiation that can cause damage (as in x-ray imaging). So, pregnant women can use it safely. The year 2017 heralded the 29th anniversary of the contrast empowerment in MRI technology. The first Gadolinium-Based Contrast Agent (GBCA), gadopentetate dimeglumine (Magnevist[®]), became available for clinical use globally in 1988 and, since then, eight further gadolinium chelates have been developed and approved in many regions worldwide.

Progress in contrast materials and the technical capabilities of MRI have increased the accuracy and utility of contrast-enhanced-MRI (CE-MRI) for many different indications. Today, CE-MRI is a valuable and established diagnostic imaging tool worldwide, used annually in approximately 30 million procedures, with more than 300 million procedures performed to date (Data on file, Bayer HealthCare). The role of CE-MRI will continue to grow in the future as new imaging techniques are integrated into clinical practice. The close relationship between clinical diagnosis and the monitoring of increasingly specific therapies is one of the most important areas for CE-

MRI use, along with research into new MRI contrast agents.

This review attempts to outline the history of contrast material development in MRI, to describe current technologic trends and clinical challenges, and to provide an outlook on potential future developments. This paper is based on previously conducted studies and does not include any new studies of human or animal subjects performed by any of the authors.

MRI and Initial Contrast Materials Research

Nuclear Magnetic Resonance (NMR) was discovered by Bloch, Bloembergen and Purcell in the 1940s (Bloch, 1946; Bloembergen et al., 1948). The first NMR images to be generated using the interaction of two magnetic gradients were not published, however, until 1973. This research was presented by Lauterbur (Lauterbur, 1973) and Mansfield (Garroway et al., 1974) who were awarded the Nobel Prize in Physiology or Medicine in 2003 for their work (Lauterbur, 2004). In 1974, Damadian was granted a patent for his NMR imaging technique, apparatus and method for detecting cancer in tissue (Damadian, 1974) and in 1977 he produced the first whole-body MRI machine that generated images of a live human body (Damadian et al., 1977).

The notion that proton relaxation times could be influenced by the presence of paramagnetic ions (with the promise of increased visibility of organs or body regions) was realized shortly after this in the late 1970s (Lauterbur et al., 1978). Research then began into suitable paramagnetic ion complexes for use as MRI contrast agents, beginning with animal studies of manganese (Mn^{2+}) compounds (Brady et al., 1982; Goldman et al., 1982; Mendonca et al., 1983) and ferric (Fe^{3+}) chloride (Young et al., 1981).

In 1982, Val Runge presented investigations of paramagnetic ions, including copper (Cu^{2+}), chromium (Cr^{3+}), Fe^{3+} , Mn^{2+} and gadolinium (Gd^{3+}) (Runge et al., 1983) outlining potential complexes that might be stable enough for clinical use as oral and intravenous contrast agents in

MRI (Runge, 2008). A research group at Schering AG, Germany (now Bayer HealthCare), led by Weinmann, had recognized that Gd^{3+} was the most effective paramagnetic ion in terms of T1 relaxivity (and thus enhancement effect), and was developing gadopentetate dimeglumine, using the commercially available diethylenetriamine penta-acetic acid chelate (Gries et al., 1981). Clinical development collaboration between Weinmann and other centers, including Runge and Brasch, led to Runge receiving the American Society of Neuroradiology Dyke Award for demonstrating the utility of gadopentetate dimeglumine-enhanced MRI for brain imaging (Runge et al., 1985). Weinmann subsequently published a seminal paper on the characteristics of, and initial study results for, gadopentetate dimeglumine (Weinmann et al., 1984) which was, as of 2008, the most cited article ever published in the *American Journal of Roentgenology* (BuiMansfield, 2006).

The first injection of gadopentetate dimeglumine in a human volunteer took place in Berlin on November 10, 1983, as part of a Phase I trial, showing uniform enhancement of the bladder (Laniado et al., 1984). Reports of the human pharmacokinetics of gadopentetate dimeglumine (Weinmann et al., 1984) and the first patient series (Carr et al., 1984) followed shortly afterward, and further clinical trials were instigated in 1985. Based on the results of these clinical trials, gadopentetate dimeglumine was approved for clinical use in the United States, Germany and

Japan in 1988: the world's first contrast medium for MRI was launched.

Action Mechanism and Pharmacology of GBCAs

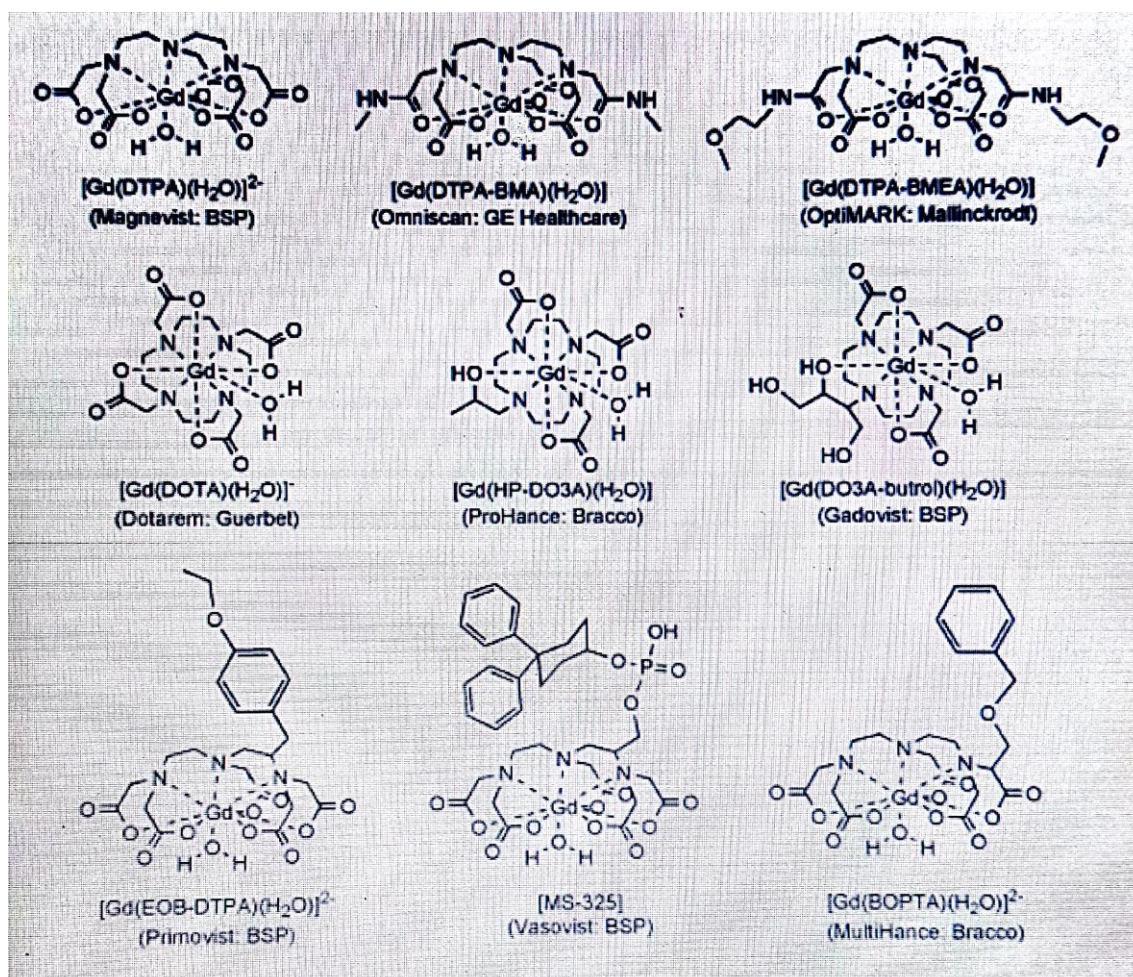
All Gadolinium-Based Contrast Agents (GBCAs) contain the paramagnetic ion of the rare earth metal gadolinium (Gd^{3+}), which possesses the most unpaired electrons of any stable ion (seven), creating a high magnetic moment that is effective at enhancing proton relaxation (Caravan et al., 1999; Lin et al., 2007). Paramagnetic contrast media shorten the T1 (longitudinal) and T2 (transversal) relaxation times of surrounding water protons to indirectly produce a signalenhancing effect (Lauffer, 1987). The efficiency of an agent to shorten relaxation times is called relaxivity, which is dependent on the ligand surrounding the Gd^{3+} ion and influenced by extrinsic factors including temperature, magnetic field strength and the tissue surroundings (water, plasma or blood). At approved clinical doses of GBCAs (typically between 0.1 and 0.3 mmol/kg body weight), the T1 relaxivity effect dominates and yields bright contrast (Cheng et al., 2012; Lauffer, 1999).

Following intravenous injection, all GBCAs distribute in the blood and extravascular– extracellular space (Aime & Caravan, 2009; Staks et al., 1994). GBCAs are biologically inert and rapidly eliminated by the kidneys, with the exception of gadoxetic acid

(Primovist[®]/Eovist[®]), gadobenate dimeglumine (Multihance[®]) and gadofosveset (Vasovist[®]/Ablavar[®]), which are in part taken up by hepatocytes and eliminated by the hepatobiliary system.

As Gd^{3+} ions are toxic, they are chelated with organic ligands to create GBCAs with either a linear or macrocyclic structure. For GBCAs with a linear structure (e.g., Magenvist, MultiHance, or Ominscan), a polyamino-carboxylic acid backbone wraps around the Gd^{3+} ion, but does not fully enclose it, whereas in macrocyclic chelates (gadobutrol [Gadovist[®]], gadoterate meglumine

[Ddexzotarem[®]], and gadoteridol [Prohance[®]]), a rigid “cage” with a preorganized cavity surrounds the ion. The structure of the GBCA determines its complex stability and stability in vivo. An in vitro study mimicking physiological serum conditions in renally impaired subjects demonstrated that linear agents, incubated over a 15-day period, could release substantial amounts of their Gd³⁺, while none of the macrocyclic agents (Gadavist, Dotarem, ProHance) showed detectable Gd³⁺ release (<0.1% during 15 days of incubation) (Frenzel et al., 2008). This study also demonstrated that for the macrocyclic agents, charge was not an influencing parameter on complex stability. However, in vivo, the majority of a GBCA dose is excreted within a few days, even in renally impaired patients; for example, the elimination half-life of gadobutrol is 90 min in healthy subjects (Staks et al., 1994) and 7–26 h in those with kidney disease (Frenzel et al., 2008; Tombach et al., 2000).



Development and Characteristics of MR Contrast Agents

After the introduction of gadopentetate dimeglumine, the use of CE-MRI as a diagnostic imaging tool has expanded rapidly. While it was understood that Gd³⁺ was the most effective paramagnetic ion for proton relaxation, other paramagnetic ions have been developed for use as MRI contrast agents, including Mn²⁺ (Bernardion et al., 1992) and iron oxide compounds (Stark et al., 1988). Today, contrast media are administered in about 25% of all MRI examinations, especially for the brain and spine, for MR angiography (MRA) and for MRI of the abdomen, breast and heart (Ferre et al., 2012).

Five further extracellular GBCAs, exhibiting the same, passive distribution and renal excretion as gadopentetate dimeglumine, have been approved for clinical use (Restrepo et al., 2012; Serrano et al., 2012) gadoterate (1989), gadoteridol (1992), gadodiamide (Omniscan[®]; 1993), gadobutrol (1998) and gadoversetamide (Optimark[™]; 1999). With the approval of gadobenate (1998) and gadoxetic acid (2005), two agents entered the market which exhibited a different pharmacokinetic profile to the other GBCAs—in addition to extracellular distribution, these agents are taken up to different degrees by hepatocytes, and thus produce a unique enhancement of liver parenchyma with partial excretion in the bile. A third group of agents are those which, after intravenous injection, remain in the circulation for prolonged periods, allowing extended

imaging times for MRA. These agents include gadofosveset and the ultrasmall superparamagnetic iron oxide (USPIO) particles (which have limited commercial availability) (Bremerich et al., 2007)

Gadolinium-based contrast agents differ in their ability to shorten relaxation times, as a function of their relaxivity and local tissue concentration (Rohrer et al., 2005) Gadobutrol was considered a 'second-generation' GBCA (Scott, 2013) owing to its higher concentration and relatively high relaxivity (and thus improved imaging capacity) compared with earlier agents. (Gadobutrol is the only GBCA formulated at a concentration of 1.0 M, twice that of other agents. Combined with its high relaxivity in plasma, gadobutrol provides the greatest T1 shortening per volume of any currently available GBCA (Sieber, 2009).

Safety of MR Contrast Agents

As a class of agents, contrast media are associated with a lower prevalence of hypersensitivity reactions than other drug classes, such as pain killers or antibiotics (Dona et al., 2012). Within contrast media, GBCAs are associated with fewer adverse drug reactions than non-ionic iodinated contrast media for X-ray and computed tomography (Forsting et al., 2010). The incidence of acute adverse reactions appears to be very low for all GBCAs (Bruder et al., 2011; Gennen et al., 2006). The favorable safety profiles of gadobutrol and gadopentetate dimeglumine have been extensively documented based on millions of applications (Gutierrez et al., 2012; Knopp et al., 2006; Matsumura et al., 2013; Prince & Palkowitsch, 2012).

In early 2006, Grobner was the first to suggest a link between administration of a GBCA and development of nephrogenic systemic fibrosis (NSF), a rare but potentially fatal disorder in patients with end-stage renal disease (Voth et al., 2011; Grobner, 2006). Bayer HealthCare immediately initiated a major research program into this issue, including basic in vitro research and toxicologic and pharmacologic animal studies (Pietsch et al., 2009) generating much of the evidence published on this topic. International expert bodies, including the Food and Drug

Administration, the European Medicines Agency and the European Society of Urological Radiology, subsequently issued recommendations concerning the stability of GBCAs (Pietsch et al., 2009) classifying macrocyclic agents as having a lower risk for the development of NSF. The reported incidence of NSF is decreasing, possibly attributable to a greater awareness of at-risk patients, lower dosing of contrast agents and the more widespread use of macrocyclic agents (Pietsch et al., 2011).

More recently, residual gadolinium has been detected in patients with normal renal function.

Abnormal T1 shortening in the dentate nucleus and globus pallidus of the brain on unenhanced

MRI was first described by Kanda et al., in patients who had previously undergone repeated CEMRI (Sieber et al., 2008). It has since been demonstrated that the strength of such T1 shortening correlates to the number of previous GBCA administrations (Sieber et al., 2008) and the dosedependent accumulation of gadolinium in the neuronal epithelium and interstitium (Sieber et al., 2009) Furthermore, akin to NSF, this phenomenon has been linked to previous administration of linear GBCA, but not macrocyclic agents (Sieber et al., 2008). The clinical consequences of gadolinium crossing the blood-brain barrier and being deposited in neuronal tissues is not yet clear, and further investigation into the biodistribution of gadolinium is warranted (Sieber et al., 2009).

Main Advances in CE-MRI

The domain of CE-MRI has experienced extensive developments (Steger-Hartmann et al., 2010).

Examples of major advances are described in the following sections.

Central Nervous System

The first studies during GBCA development showed that CE-MRI had utility for brain imaging (Steger-Hartmann et al., 2009) due to the possibility to enhance areas with a disrupted blood-brain barrier corresponding to tumors and many inflammatory/infectious disorders. GBCAs were also shown to enhance tumors with a clear delineation and differentiation from perifocal oedema. Imaging of primary and secondary central nervous system (CNS) tumors is now a major clinical application of routine CE-MRI with superior imaging performance and greater versatility compared with other imaging techniques including CT (Thomsen et al., 2013). CE-MRI provides information on the location, classification, and grade of lesions, assisting in directing biopsy, treatment planning and monitoring of the response to therapy. Higher relaxivity agents higher field strengths (e.g., 3 T or higher) and time-resolved imaging have improved image spatial and temporal resolution and quality, increasing sensitivity for detecting smaller metastatic lesions (Becker et al., 2012). Other current applications of CE-MRI in the CNS include the assessment of vascular disease (stroke and vascular malformations), and inflammatory, neurodegenerative and infectious diseases.

Contrast-enhanced magnetic resonance imaging is the gold standard for imaging patients with multiple sclerosis (MS). Applications of MRI in MS were first investigated in the early 1980s, where the technique demonstrated superior ability to detect lesions in the brain and spinal cord compared with CT (Wang et al., 2011). Enhancing

MS lesions on CE-MRI signify new inflammatory activity and a breakdown of the blood–brain barrier, whereas active and inactive lesions may be indistinguishable on unenhanced T2-weighted images. This enhancement pattern is valuable to monitor MS lesion activity and response to treatment (Kanda et al. 2014). The value of CE-MRI for management of MS was reflected by inclusion of this modality in the McDonald criteria, originally in 2001 and later in the 2005 and 2010 revised guidelines [93,94]. The principle of CNS perfusion imaging was first described in a rat model of cerebral blood volume and cerebral blood flow in 1988. Ten years later, perfusion imaging was routinely used to demonstrate poorly perfused brain tissue in stroke patients that was not observable on T2weighted sequences (Errante et al., 2014). The kinetic parameters associated with perfusion imaging, such as relative cerebral blood flow (rCBF) and relative cerebral blood volume (rCBV) estimates, have been defined, quantified, and validated against established techniques such as SPECT (single-photon emission CT). Perfusion sequences are now widely incorporated in MRI protocols to quantify the extent of ischemia and hypoperfused tissue, with capability to target and optimize reperfusion therapy.

Functional MRI techniques such as perfusion imaging are being utilized for brain tumor imaging, based on the principle of increased tumor vascularity. Determination of a threshold value for rCBV on CE-MRI has shown predictive value for differentiating high- and low-grade cerebral tumors and such a threshold can predict lesion progression and the outcome for patients with such tumors (Quattrocchi et al., 2015). Other perfusion parameters, including mean transit time and time to peak enhancement, have also been investigated as predictive markers in brain tumor imaging, although they are subject to variability and their biological relevance remains unclear. Dynamic contrast-enhanced (DCE) MRI and dynamic susceptibility contrast (DSC) MRI have also found a role in tumor imaging to assess vascular permeability and angiogenesis, respectively. Furthermore, DCE and DSC are commonly applied in acute stroke imaging to assist the differential evaluation of reversibly and irreversibly injured tissue.

Perfusion imaging techniques are advancing rapidly and a recently reported fast, time-resolved sequence with good spatial and temporal resolution has shown promise for the estimation of rCBF and rCBV for MS lesions; this technique is predicted to improve the quantification of haemodynamics in a range of cerebral pathologies (Kanda et al., 2015).

Magnetic Resonance Angiography

In the early 1990s, the imaging technique of contrast-enhanced MRA was described which ultimately allowed less invasive and more rapid assessment of the anatomy and blood flow of vascular structures than intra-arterial digital subtraction angiography (DSA), without the radiation burden of CT-based angiography techniques. Injecting contrast while the patient was inside the scanner and synchronizing the bolus peak arterial phase with acquisition of central kspace data demonstrated preferential arterial enhancement, without excessive venous or background tissue enhancement, providing favorable sensitivity and specificity for the diagnosis of stenoses and occlusions (McDonald et al., 2015). Although signal-to-noise ratio (SNR) on MR images usually decreases with accelerated imaging, development of a faster, breath-hold abdominal MRA technique in 1995 surprisingly provided improvements of 25–50% and 60–120% in SNR and contrast-to-noise ratio, respectively, with significantly reduced motion-related image blurring compared to the slower free breathing technique. Introduction of a time-resolved sequence in 1996, using view sharing with oversampling of the center of k-space, provided additional temporal information on blood flow dynamics, while maintaining the excellent delineation of vessels provided by the breath-hold technique, and reducing the flow-related artifacts that were sometimes seen. It was further realized, in 1997, that correct GBCA bolus timing could approximately double SNR in the aorta and portal vein, and this subsequently led to the development of a number of semi-automated bolus detection tools for optimization of CEMRA acquisition. A further advance in MRA came in 1998 with the introduction of moving-bed techniques allowing the GBCA bolus to be tracked over four or five fields of view, providing

‘head-to-toe’ angiographic images in a single examination (Port et al., 2008).

Today, CE-MRA is widely used for imaging the vascular anatomy in patients with known or suspected peripheral arterial occlusive or aneurysmal disease, as well as various less commonly encountered conditions that affect the non-coronary vasculature. Through advances in technology and the availability of suitable contrast agents, CE-MRA has evolved into a real-time imaging technique that is a highly valuable alternative to CT angiography and intra-arterial DSA, with the advantages of avoiding ionizing radiation, iodinated contrast agents, and the need for arterial puncture or manipulation (as required for DSA), making MRA particularly useful in patients requiring repeated imaging. Radial/spiral acquisitions that oversample the center of kspace, combined with compressed sensing technology and iterative Bayesian reconstruction techniques, promise to accelerate these sparse MRA data acquisitions by several orders of magnitude (Rohrer et al., 2005).

Cardiac Imaging

Gadolinium-based contrast agent wash-in and wash-out characteristics were initially described to differentiate infarcted and normal myocardial tissue in a rabbit model in 1996, with marked differences in contrast kinetics between normal tissue, infarct rim and infarct core regions, which correlated with the severity of microvascular damage. Differentiation of areas of damaged myocardium from areas that are structurally intact using CE-MRI at 10–20 min p.i. has been termed ‘delayed gadolinium enhancement’ or ‘late gadolinium enhancement’ (LGE) imaging. Various studies have found LGE imaging to be a fast, robust, and highly valuable method to determine myocardial viability in patients with left ventricular dysfunction. The likelihood of improvement in regional myocardial contractility following revascularization is negatively correlated with the size of a myocardial infarction, as depicted by the transmural extent of hyperenhancement at pretreatment CE-MRI (Schmitt, 2007). LGE has also proved to be an accurate measure to detect myocardial scars, myocardial fibrosis, and myocarditis (Port et al., 2008).

Advances in MR hardware and software have also led to the widespread adoption of MR myocardial perfusion imaging (MPI) in patients with suspected coronary artery disease (CAD). In MR-MPI, the initial upslope of dynamic (time-resolved) perfusion CE-MRI signal enhancement under rest and stress (adenosine stimulation) accurately depicted significant CAD, compared with invasive coronary angiography as a Ref. Receiver operating characteristic analyses revealed a clear cut-off value enabling determination of significant CAD, with high sensitivity and specificity (88% and 90%, respectively) (Scott, 2013). A meta-analysis of trials investigating cardiac SPECT, positron emission tomography (PET) and MRI perfusion imaging confirmed the high diagnostic accuracy of MR-MPI for detection of obstructive CAD, with the benefit of avoiding the ionizing radiation associated with the other techniques. The superiority of combined LGE and perfusion cardiac imaging over SPECT for the diagnosis of coronary artery disease has also recently been established in a large, prospective multicenter trial. 3.0 T CE whole-heart coronary angiography is undergoing preliminary clinical investigations and achieving encouraging results (Dona et al., 2012). If this technique proves successful, it may form part of a ‘one-stop-shop’ examination of CAD, providing information on the anatomy of the heart and the large blood vessels (including the coronary artery), ventricular wall motion, cardiac function, the heart valves, myocardial perfusion, myocardial viability and cardiac metabolism.

Today, cardiac MRI has the capability to visualize cardiac function and morphology, and has become a standard imaging modality in a range of clinical applications including assessment of valvular disease, myocarditis and cardiomyopathies, and congenital heart disease (Bruder et al., 2011).

Abdomen

The first CE-MRI examination of the liver was performed in 1984, as part of a case series investigating the efficacy and safety of gadopentetate dimeglumine-enhanced MRI. Assessment of the dynamic CE-MRI enhancement pattern has become key for the differentiation of benign and malignant lesions in the liver, pancreas and kidneys, as well as elsewhere in the body. Major advances in this field were the introduction of fast breath-hold techniques and effective respiratory triggering, which reduced respiratory- and motion-induced artifacts while improving the sensitivity of imaging (Geenen et al., 2006).

Another major advance was the advent of hepato-specific contrast agents. The first liver-specific CE-MRI results were published in 1991, describing manganese dipyridoxal diphosphate enhancement of the liver parenchyma and clearance into the gallbladder (this agent has currently limited worldwide availability). Gadobenate dimeglumine was then demonstrated to exhibit a small amount of hepatic excretion in humans (3–5%), meaning that a liver-specific imaging phase could be discerned during delayed imaging (1–2 h p.i.) (Knopp et al., 2006).

The agent gadoxetic acid (primovist/eovist) was developed as a highly liver-specific contrast medium. Gadoxetic acid is excreted almost equally via the liver and kidneys in humans and provides an earlier hepato-specific imaging time (15–20 min p.i.) compared with gadobenate (Prince et al., 2012). A seminal manuscript by Weinmann, published in 1991, described the preclinical results for gadoxetic acid, highlighting its protein binding properties, low toxicity and uptake properties in rat hepatocytes, predicting gadoxetic acid to play a future role as a hepatobiliary contrast agent for MRI in clinical practice. The clinical trials in humans that followed established the value of gadoxetic acid for liver MRI, and more specifically for the detection and differentiation of focal liver lesions in the cirrhotic and noncirrhotic liver. Reflecting the value of gadoxetic acid-enhanced MRI, this imaging method was included in the 2010 guidelines of the Japan Society of Hepatology for the diagnosis of hepatocellular carcinoma in chronic liver disease. More recently, further applications of gadoxetic acid-enhanced MRI have been investigated, including for cholangiopancreatography and biliary imaging. The potential utility of gadoxetic acid-enhanced MRI has also been suggested for the assessment of the liver pre- and post-treatment (surgery or locoregional therapy), including the quantitative and regional assessment of liver function (Voth et al., 2006).

Contrast-enhanced magnetic resonance imaging has also proven useful, alongside multidetector CT, for accurate and sensitive characterization of renal masses; however, MRI has shown particular value as a problem-solving tool in this field, and advanced techniques, such as perfusion and diffusion imaging, are now being investigated for the assessment of renal lesions and renal function (MR nephrography).

CE-MR enterography for imaging the small bowel provides similar spatial resolution and improved contrast resolution compared to CT for investigation of gastrointestinal tumors and inflammatory bowel disease, and it shows promise for the future in terms of differentiating active from chronic bowel disease and non-invasive monitoring of response to therapy. The advantage of eliminating ionizing radiation with CE-MRI compared with CT is particularly important in young patients with inflammatory bowel disease who require numerous repeated examinations over many years.

Contrast-enhanced magnetic resonance imaging is becoming a standard modality to image malignancies in the pelvis, with analysis of dynamic contrast kinetics able to aid visualization of tumor vascularization and differentiation of benign from malignant prostate and ovarian tumors. For such tumors, improved diagnostic confidence in assessment of lesion type, extension and response to therapy has been demonstrated for multiparametric MRI techniques combining DCE with other functional parameters, particularly diffusion-weighted imaging (DWI) (Grobner, 2006).

Breast

Contrast-enhanced magnetic resonance imaging of breast lesions was reported in a preliminary study in 1986, and was shown to be more accurate than X-ray mammography and unenhanced MRI. In the following years, various technical developments were described (Carr et al., 1984). CE-MRI has since been demonstrated to detect more ductal carcinoma in situ than mammography, and in particular more high-grade disease, suggesting that CE-MRI is superior to mammography for diagnosis of the most clinically relevant, potentially invasive tumors. An explanation for the difference in performance between these modalities is that mammography demonstrates microcalcifications due to apoptosis of slowly growing cancers, whereas MRI detects changes in the local microvasculature indicative of aggressively growing cancers. CEMRI has also been shown to be highly sensitive for the detection of cancer foci in the contralateral breast of women diagnosed with unilateral disease. Furthermore, neither mammography nor ultrasound could improve the cancer yield provided by CE-MRI alone when screening women at risk (Lin & Brown, 2007).

DCE enhancement kinetics have shown value for the evaluation of mass-like breast tumors, especially for morphologically equivocal lesions, with characteristic signal time–intensity curves able to differentiate benign from malignant tumors. Following early initial tumor enhancement, a signal intensity decline (type III ‘washout’ curve) or plateau (type II curve) is characteristic of invasive breast cancer, whereas benign masses tend to exhibit a type I curve with ‘persistent’ signal enhancement.

Today, CE-MRI is an established tool for determining the morphological and functional characteristics of breast tumors, and is recommended by international societies for screening women with >20% lifetime risk of breast cancer, to aid exact local staging of the extent of disease, as a guide for biopsy, and to evaluate treatment response (Caravan et al., 1999).

Musculoskeletal System

Magnetic resonance imaging has been used to image the musculoskeletal system since the early days of the modality, as MRI demonstrated good soft tissue contrast, spatial resolution and multiplanar capabilities, and sequences could be adapted for optimal contrast between muscle, bone marrow and abnormal tissue. The indications for musculoskeletal MRI fall into three main categories: tumors, infectious diseases and joint damage. CE-MRI is employed to gain additional information in cases of complicated osseous and soft-tissue infection (especially when extent and necrosis are of concern), and for the evaluation of articular injuries and post-operative joint status. For joint assessment, MR arthrography has become a useful alternative to conventional MRI, with GBCA administration performed intravenously (indirect arthrography) or into the target joint (direct arthrography). Higher magnetic field strength, specialized coils, and improvements in pulse sequences and post-processing have led to increased SNR and soft tissue contrast. Nonetheless, more recent technological advances have furthered the capabilities of musculoskeletal MRI, including kinematic imaging of joint motion, MR spectroscopy and cartilage mapping (Staks et al., 1994).

Current Technological Trends and Clinical Challenges

Contrast-enhanced magnetic resonance imaging has become accepted as a valuable non-invasive, efficient and safe diagnostic imaging modality that is utilized in radiology departments worldwide. Current trends in the use of existing MR technologies are toward a greater standardization—and simplification—of protocols across centers, with the benefits of uniform performance and interpretation of imaging studies.

Continuing research is also extending the applications of current contrast agents, so that individual agents can now be used to image an increasing number of body regions in a single examination.

MRI acquisition times have shortened substantially over the past 25 years by increasing gradient performance and with new acquisition methods utilizing k-space undersampling, parallel imaging and, more recently, compressed sensing. The wider availability of MRI scanners with a 3 T field strength has also brought possibilities for higher image quality and shorter scan times (Tombach et al., 2000).

The growing importance of MRI as a diagnostic tool has been underpinned by its capacity for multiparametric data acquisition, including DWI, DCE, elastography and MR spectroscopy, alongside conventional MRI protocols. Multiparametric imaging has enabled more accurate assessment of normal and disease-associated tissue characteristics in terms of cellularity (diffusion restriction), vascularization (DSC), permeability (DCE), fibrosis and metabolite levels, leading to greater certainty of diagnosis and improved patient outcome. Multiparametric MRI is advancing imaging capabilities in many fields, with a special focus on indications where anatomical imaging alone has in the past been associated with limited accuracy, such as breast and prostate cancer imaging (Bernardino, 1992). A recent trend in the development of MRI has been the investigation of integrated multimodality imaging, particularly MR/PET (Kanda et al., 2015). While PET/CT has been established as a diagnostic tool in cancer imaging for the past decade, MR/PET offers exciting possibilities for gathering extensive morphologic and hybrid (i.e. both PET and MRI) functional information. More research is required to establish the most appropriate clinical applications of MR/PET, based on diagnostic performance, technical feasibility, practicality and cost in relation to existing techniques. MR/PET techniques will also require changes in data acquisition, data processing, and image processing and interpretation when compared with PET/CT.

The fast pace of technological innovation in MR is in itself a challenge for clinical practitioners. CE-MRI acquisition techniques are continually changing, and the modern radiologist must keep abreast of the latest developments while ensuring that others on the clinical team (nurses, technicians, etc.) are also appropriately educated and trained. As the reported applications of MRI continue to grow in the literature, there is a related need for expert recommendations to provide guidance on the optimal parameters and protocols, interpretation and reporting of the imaging results. For example, as described previously, dynamic CE-MRI perfusion parameters can aid in grading and predicting the progression of brain tumors and show promise as markers to monitor response to therapy; however, the variations in practice observed between centers indicate a need for a greater standardization of protocols and the utilization of the latest diagnostic algorithms (Errante et al., 2014). The role of CE-MRI in disease screening programs is an ongoing topic of discussion, with both health-economic and clinical repercussions. CE-MRI has demonstrated high sensitivity and specificity for the detection of liver cancer and, as discussed above, CE-MRI of the breast provides a high cancer yield and is recommended for screening women at high risk. Currently, the imaging time and cost of a standard CE-MRI examination limits the use of MRI in screening programs. However, the feasibility of an MRI examination that uses limited sequences but retains sufficient sensitivity for screening is under discussion. This approach could shift the role of MRI in screening, decrease the cost per MRI examination and make MRI screening more cost-effective.

Future Perspectives

As the field of CE-MRI expands, there are many current research avenues and trends that in the future could prove important to clinical practice. In the following sections, four of these potentially interesting areas are discussed; however, we acknowledge that many more exciting avenues exist.

Technological Advances: Higher Acceleration

Newer signal processing technologies, such as compressed sensing and Bayesian iterative reconstruction methods are allowing the rapid acquisition of undersampled k-space data, permitting entire 3D images to be reconstructed from relatively few measurements. This technique allows acquisition of 3D data sets with preserved spatial resolution in a fraction of the standard examination time. Preliminary studies are demonstrating the capabilities of this technology, including clear visualization of the cerebral arteries and many branches on wholehead CE-MRA images (generated with an acceleration factor >100, 1 mm³ resolution and a frame rate of approximately one full 3D dataset per second), functional cardiac MRI of the whole heart within one breath hold or using a free breathing technique, and high-resolution dynamic liver imaging at four frames per second (McDonald et al, 2015).

This approach is likely to have an impact in many areas, initially for dynamic processes but eventually for all clinical MRI procedures, leading to an improved patient care through shorter and less invasive diagnostic examinations.

Role of Contrast Agents

Contrast media will be indispensable in most MRI examinations in the foreseeable future. The type of contrast medium selected and the dose that is injected will likely reflect changes in knowledge and techniques. Greater availability of MRI scanners with extended field of view coils and a 3 T field strength has provided an opportunity to improve the sensitivity of imaging and to allow contrast dose reduction without compromising image quality. Since a dose of contrast agent redistributes throughout the entire body, scanners with large coil arrays can be used to quickly screen extensive areas of anatomy, dramatically increasing the information obtained with a single injection (compared to imaging with scanners limited to a single station field of view). The number of CE-MRI procedures performed globally is likely to grow in the future, as the applications of MRI expand, as this modality becomes available to more patients, and as the information obtained from a single contrast injection increases. Technological advances are likely to facilitate the optimization of MRI protocols, reduce examination time while enriching the value of the MRI examination to the patient.

Higher Relaxivity Contrast Agents

Despite the major advances in CE-MRI in recent times, there are pathologies that cannot be fully assessed by MRI. In order to increase the sensitivity of CE-MRI in certain pathologies, contrast agents with substantially higher relaxivity will be required.

The efficiency of GBCAs, defined by their T1-relaxivity, is in part dependent on the number of water molecules directly bound to the Gd^{3+} complex (q), their mean residence time (τ_m) and the number and residence times of water molecules in the second hydration sphere (Quattrocchi et al., 2015). GBCAs induce proton relaxation by creating a fluctuating magnetic field, which can arise from tumbling of the molecule in solution (described by the rotational correlation time, τ_R) and excitation and relaxation of electrons in the Gd^{3+} . Molecular size, rigidity of the Gd^{3+} complex binding to a larger carrier molecule, and physiological protein binding all affect τ_R .

At typical clinical magnetic field strengths (0.5–3 T), the greatest increases of T1-relaxivity for GBCAs have been achieved by slowing the tumbling (increasing τ_R) of complexes with $q = 1$ and water exchange rates (τ_m) of 10–30 ns (Wang et al., 2011). Relaxivity can be increased further by increasing q to 2; however, this reduces the stability of the complex. Water exchange dynamics and relaxivity can also be adapted by altering groups of atoms within the Gd^{3+} complex. Tumbling can be slowed (and relaxivity increased) by assembling larger molecules (nanometre scale) with numerous paramagnetic centers, but these molecules are limited in their distribution within the body due to their physical size (molecules >5 to 10 nm cannot freely leave the blood stream). Examples of this concept are experimental Gd complexes covalently bound to albumin, dextran or macromolecules (dendrimers), which have shown T1-relaxivities 3–5 times greater than clinically available agents. For magnetic field strengths of 3 T and above, the highest relaxivities can be achieved with intermediate τ_R (≤ 1 ns) and $\tau_m < 2$ ns; however, such water residence times would be close to the shortest currently observed (1 ns) (Thomsen et al., 2013). The best strategy for raising relaxivity at high field strength is probably a moderate reversible binding to plasma proteins, a large second sphere of water molecules surrounding the Gd complex, and an increase in q ; however, the benefits of the latter modification should be weighed against any reduction in complex stability. A number of studies using $q = 2$ and $q = 3$ have investigated this concept.

II APPLICATIONS OF HIGHER RELAXIVITY CONTRAST AGENTS

TARGETED IMAGING

Significant increases in relaxivity will allow substantial reductions in dose for novel agents and will facilitate the development of targeted/tissue-specific contrast media. Tissue-specific contrast agents are already available, such as gadoxetic acid, which is taken up by a hepatocyte uptake transporter (organic anion-transporting polypeptide 8) in liver parenchyma (Sieber et al., 2009) and the superparamagnetic iron oxide particles (SPIOs), which are sequestered by phagocytic Kupffer cells in the reticuloendothelial system of the liver. Other targeted agent approaches are at an experimental stage: investigations of ultrasmall SPIOs for imaging macrophage activity in lymph nodes and atherosclerotic plaque have been performed, as has labeling of tumors with monoclonal antibodies conjugated to paramagnetic complexes or superparamagnetic nanoparticles. However, the sensitivities of these techniques are not currently adequate for clinical applications, and new agents with significantly increased relaxivity targeted to specific tissues or disease processes will be required. One such experimental agent is EP-2104R, a molecule containing four Gd-complexes that binds with good specificity to fibrin, where it demonstrates a relaxivity per molecule approximately 25 times higher than a conventional GBCA at 1.4 T (Steger-Hartmann et al., 2009). The strong fibrin binding, selectivity and high relaxivity of EP-2104R enabled a clear depiction of occlusive intracranial thrombi in a rat embolic stroke model, where the Gd^{3+} concentration in the clot was 18-fold higher than in the blood pool. This agent has also demonstrated good visualization of thrombi in a swine model of pulmonary embolism, and could depict thrombi in the arterial and venous systems and hearts of patients (Steger-Hartmann et al., 2009).

Monitoring Response to Therapy

Early information on disease progression and response to therapy has considerable potential benefits for patient management, by promptly highlighting a need to shift therapeutic approaches and by providing cost savings if expensive therapies (e.g., anti-angiogenic agents) are quickly evaluated to be unsuccessful. A number of quantitative DCE and perfusion parameters are now considered biomarkers with value for the prediction and monitoring of therapeutic response, particularly to date in the oncologic and cardiologic specialties (Becker et al., 2012). For example, in oncology, perfusion mapping (as a surrogate measure of blood flow) correlates with response to tyrosine-kinase inhibitor therapy in patients with renal tumors, and quantitative kinetic parameters of lesion enhancement at DCE can predict whether triple-negative breast cancer patients will respond to neoadjuvant chemotherapy. Animal studies have suggested that quantitative tumor vascularity and perfusion parameters can act as surrogate descriptors for the effect of sorafenib therapy on prostate carcinoma within a week and that, in conjunction with novel contrast agents, the DCE MRI profile is able to indicate early (within 24 h) endothelial permeability changes following bevacizumab therapy in a melanoma model (Steger-Hartmann et al., 2009).

III CONCLUSION

The domain of contrast materials in MRI has expanded beyond expectations since the approval of the first MRI contrast agent, gadopentetate dimeglumine, in the last three decades, and it continues to evolve. Today, CE-MRI is a valuable and established modality for multiple indications in many body regions. New techniques are bringing exciting novel possibilities for MRI, alongside associated clinical challenges.

REFERENCES

- [1]. Aime S, Caravan P. Biodistribution of gadolinium-based contrast agents, including gadolinium deposition. *J Magn Reson Imaging*. 2009;30(6):1259–1267.
- [2]. Becker S, Walter S, Witzke O, Kreuter A, Kribben A, Mitchell A. Application of gadolinium-based contrast agents and prevalence of nephrogenic systemic fibrosis in a cohort of end-stage renal disease patients on hemodialysis. *Nephron Clin Pract*. 2012;121(1–2):c91–c94.
- [3]. Bernardino ME, Young SW, Lee JK, Weinreb JC. Hepatic MR imaging with Mn-DPDP: safety, image quality, and sensitivity. *Radiology*. 1992;183(1):53–58.
- [4]. Bloch F. Nuclear induction. *Phys Rev*. 1946;70(7–8):460–474.
- [5]. Bloembergen N, Purcell EM, Pound RV. Relaxation effects in nuclear magnetic resonance absorption. *Phys Rev*. 1948;73(7):679–712.
- [6]. Brady TJ, Goldman MR, Pykett IL, et al. Proton nuclear magnetic resonance imaging of regionally ischemic canine hearts: effect of paramagnetic proton signal enhancement. *Radiology*. 1982;144(2):343–347.
- [7]. Bremerich J, Bilecen D, Reimer P. MR angiography with blood pool contrast agents. *Eur Radiol*. 2007;17(12):3017–3024.
- [8]. Bruder O, Schneider S, Nothnagel D, et al. Acute adverse reactions to gadolinium-based contrast agents in CMR: multicenter experience with 17,767 patients from the EuroCMR Registry. *JACC Cardiovasc Imaging*. 2011;4(11):1171–1176.
- [9]. Bui-Mansfield LT. Top 100 cited AJR articles at the AJR's Centennial. *AJR Am J Roentgenol*. 2006;186(1):3–6.
- [10]. Caravan P, Ellison J, McMurry T, Lauffer R. Gadolinium(III) chelates as MRI contrast agents: structure, dynamics, and applications. *Chem Rev*. 1999;99(9):2293–2352.
- [11]. Carr DH, Brown J, Bydder GM, et al. Gadolinium-DTPA as a contrast agent in MRI: initial clinical experience in 20 patients. *AJR Am J Roentgenol*. 1984;143(2):215–224.
- [12]. Cheng KT, Cheng HY, Leung K. Clinical use of gadobutrol for contrast-enhanced magnetic resonance imaging of neurological diseases. *Rep Med Imaging*. 2012;2012(5):15–22.
- [13]. Damadian R, Goldsmith M, Minkoff L. NMR in cancer: XVI. FONAR image of the live human body. *Physiol Chem Phys*. 1977;9(1):97–100.
- [14]. Damadian R. Apparatus and method for detecting cancer in tissue. Patent 3,789,832. Feb, 1974.
- [15]. Dona I, Blanca-Lopez N, Torres MJ, et al. Drug hypersensitivity reactions: response patterns, drug involved, and temporal variations in a large series of patients. *J Investig Allergol Clin Immunol*. 2012;22(5):363–371.
- [16]. Errante Y, Cirimele V, Mallio CA, Di Lazzaro V, Zobel BB, Quattrocchi CC. Progressive increase of T1 signal intensity of the dentate nucleus on unenhanced magnetic resonance images is associated with cumulative doses of intravenously administered gadodiamide in patients with normal renal function, suggesting dechelation. *Invest Radiol*. 2014;49(10):685–690.
- [17]. Ferré J-C, Shiroishi MS, Law M. Advanced techniques using contrast media in neuroimaging. *Magn Reson Imaging Clin N Am*. 2012;20(4):699–713.
- [18]. Forsting M, Palkowitsch P. Prevalence of acute adverse reactions to gadobutrol—a highly concentrated macrocyclic gadolinium chelate: review of 14,299 patients from observational trials. *Eur J Radiol*. 2010;74(3):e186–e192.
- [19]. Frenzel T, Lengsfeld P, Schirmer H, Hutter J, Weinmann HJ. Stability of gadolinium-based magnetic resonance imaging contrast agents in human serum at 37 degrees C. *Invest Radiol*. 2008;43(12):817–828.
- [20]. Garroway AN, Grannell PK, Mansfield P. Image formation in NMR by a selective irradiative process. *J Phys C Solid State Phys*. 1974;7(24):L457.
- [21]. Geenen RWF, Krestin GP. Non-tissue specific extracellular MR contrast media. In: Thomsen HS, editor. *contrast media*. Springer: Berlin Heidelberg; 2006. pp. 107–114.
- [22]. Goldman MR, Brady TJ, Pykett IL, et al. Quantification of experimental myocardial infarction using nuclear magnetic resonance imaging and paramagnetic ion contrast enhancement in excised canine hearts. *Circulation*. 1982;66(5):1012–1016.
- [23]. Gries H, Rosenberg D, Weinmann HJ. Patent application. Patent DE-OS 3129906 A1. 1981.
- [24]. Grobner T. Gadolinium—a specific trigger for the development of nephrogenic fibrosing dermopathy and nephrogenic systemic fibrosis? *Nephrol Dial Transplant*. 2006;21(4):1104–1108.
- [25]. Gutierrez JE, Koenig S, Breuer J. Overview on the efficacy and safety of gadobutrol: an MRI contrast agent for the CNS, body and vessels. *Imaging Med*. 2012;4(1):25–40.

- [26]. Kanda T, Fukusato T, Matsuda M, et al. Gadolinium-based contrast agent accumulates in the brain even in subjects without severe renal dysfunction: evaluation of autopsy brain specimens with inductively coupled plasma mass spectroscopy. *Radiology*. 2015;276(1):228–232.
- [27]. Kanda T, Ishii K, Kawaguchi H, Kitajima K, Takenaka D. High signal intensity in the dentate nucleus and globus pallidus on unenhanced T1-weighted MR images: relationship with increasing cumulative dose of a gadolinium-based contrast material. *Radiology*. 2014;270(3):834–841.
- [28]. Knopp MV, Balzer T, Esser M, Kashanian FK, Paul P, Niendorf HP. Assessment of utilization and pharmacovigilance based on spontaneous adverse event reporting of gadopentetate dimeglumine as a magnetic resonance contrast agent after 45 million administrations and 15 years of clinical use. *Invest Radiol*. 2006;41(6):491–499.
- [29]. Laniado M, Weinmann HJ, Schoerner W, Felix R, Speck U. First use of GdDTPA/dimeglumine in man. *Physiol Chem Phys Med NMR*. 1984;16(2):157–165.
- [30]. Lauffer RB. Magnetic resonance contrast media: principles and progress. *Magn Reson Q*. 1990;6(2):65–84.
- [31]. Lauffer RB. Paramagnetic metal complexes as water proton relaxation agents for NMR imaging: theory and design. *Chem Rev*. 1987;87(5):901–927.
- [32]. Lauterbur PC, Dias MHM, Rudin AM. Augmentation of tissue water proton spin-lattice relaxation rates by in vivo addition of paramagnetic ions. In: Dutton P, editor. *Electrons to tissues*. London: Academic Press; 1978. p. 752–9.
- [33]. Lauterbur PC. All science is interdisciplinary—from magnetic moments to molecules to men. In: Frängsmyr T, editor. *Les Prix Nobel. The Nobel Prizes 2003*. Stockholm: Nobel Foundation; 2004.
- [34]. Lauterbur PC. Image formation by induced local interactions: examples employing nuclear magnetic resonance. *Nature*. 1973;242(5394):190–191.
- [35]. Lin SP, Brown JJ. MR contrast agents: physical and pharmacologic basics. *J Magn Reson Imaging*. 2007;25(5):884–899.
- [36]. Mansfield P. Snap-shot MRI. In: Frängsmyr T, editor. *Les Prix Nobel. The Nobel Prizes 2003*. Stockholm: Nobel Foundation; 2004.
- [37]. Matsumura T, Hayakawa M, Shimada F, et al. Safety of gadopentetate dimeglumine after 120 million administrations over 25 years of clinical use. *Magn Reson Med Sci*. 2013;12(4):297–304.
- [38]. McDonald RJ, McDonald JS, Kallmes DF, et al. Intracranial gadolinium deposition after contrast-enhanced MR imaging. *Radiology*. 2015;275(3):772–782.
- [39]. Mendonca-Dias MH, Gaggelli E, Lauterbur PC. Paramagnetic contrast agents in nuclear magnetic resonance medical imaging. *Semin Nucl Med*. 1983;13(4):364–376.
- [40]. Pietsch H, Lengsfeld P, Jost G, Frenzel T, Hutter J, Sieber MA. Long-term retention of gadolinium in the skin of rodents following the administration of gadolinium-based contrast agents. *Eur Radiol*. 2009;19(6):1417–1424.
- [41]. Pietsch H, Lengsfeld P, Steger-Hartmann T, et al. Impact of renal impairment on long-term retention of gadolinium in the rodent skin following the administration of gadolinium-based contrast agents. *Invest Radiol*. 2009;44(4):226–233.
- [42]. Pietsch H, Pering C, Lengsfeld P, et al. Evaluating the role of zinc in the occurrence of fibrosis of the skin: a preclinical study. *J Magn Reson Imaging*. 2009;30(2):374–383.
- [43]. Pietsch H, Raschke M, Ellinger-Ziegelbauer H, et al. The role of residual gadolinium in the induction of nephrogenic systemic fibrosis-like skin lesions in rats. *Invest Radiol*. 2011;46(1):48–56.
- [44]. Port M, Idee JM, Medina C, Robic C, Sabatou M, Corot C. Efficiency, thermodynamic and kinetic stability of marketed gadolinium chelates and their possible clinical consequences: a critical review. *Biometals*. 2008;21(4):469–490.
- [45]. Prince MR, Palkowitsch P. Safety of gadobutrol in 15,508 patients, data from the interim analysis of the GARDIAN study, a global multicenter prospective non-interventional study. In: *The annual meeting of the Radiological Society of North America*; November 25–30, 2012 (abstract SSQ08-04).
- [46]. Quattrocchi CC, Mallio CA, Errante Y, et al. Gadodiamide and dentate nucleus T1 hyperintensity in patients with meningioma evaluated by multiple follow-up contrast-enhanced magnetic resonance examinations with no systemic interval therapy. *Invest Radiol*. 2015;50(7):470–472.
- [47]. Restrepo CS, Tavakoli S, Marmol-Velez A. Contrast-enhanced cardiac magnetic resonance imaging. *Magn Reson Imaging Clin N Am*. 2012;20(4):739–760.
- [48]. Rohrer M, Bauer H, Mintorovitch J, Requardt M, Weinmann HJ. Comparison of magnetic properties of MRI contrast media solutions at different magnetic field strengths. *Invest Radiol*. 2005;40(11):715–724.
- [49]. Runge VM, Clanton JA, Price AC, et al. Dyke Award. Evaluation of contrast-enhanced MR imaging in a brain-abscess model. *AJNR Am J Neuroradiol*. 1985;6(2):139–147.
- [50]. Runge VM, Stewart RG, Clanton JA, et al. Work in progress: potential oral and intravenous paramagnetic NMR contrast agents. *Radiology*. 1983;147(3):789–791.
- [51]. Runge VM. Notes on “Characteristics of gadolinium-DTPA complex: a potential NMR contrast agent” *AJR Am J Roentgenol*. 2008;190(6):1433–1434.
- [52]. Schmitt-Willich H. Stability of linear and macrocyclic gadolinium based contrast agents. *Br J Radiol*. 2007;80(955):581–582.
- [53]. Scott L. Gadobutrol: a review of its use for contrast-enhanced magnetic resonance imaging in adults and children. *Clin Drug Investig*. 2013;33(4):303–314.
- [54]. Serrano LF, Morrell B, Mai A. Contrast media in breast imaging. *Magn Reson Imaging Clin N Am*. 2012;20(4):777–789.
- [55]. Sieber MA, Lengsfeld P, Frenzel T, et al. Preclinical investigation to compare different gadolinium-based contrast agents regarding their propensity to release gadolinium in vivo and to trigger nephrogenic systemic fibrosis-like lesions. *Eur Radiol*. 2008;18(10):2164–2173.
- [56]. Sieber MA, Lengsfeld P, Walter J, et al. Gadolinium-based contrast agents and their potential role in the pathogenesis of nephrogenic systemic fibrosis: the role of excess ligand. *J Magn Reson Imaging*. 2008;27(5):955–962.
- [57]. Sieber MA, Pietsch H, Walter J, Haider W, Frenzel T, Weinmann HJ. A preclinical study to investigate the development of nephrogenic systemic fibrosis: a possible role for gadolinium-based contrast media. *Invest Radiol*. 2008;43(1):65–75.
- [58]. Sieber MA, Steger-Hartmann T, Lengsfeld P, Pietsch H. Gadolinium-based contrast agents and NSF: evidence from animal experience. *J Magn Reson Imaging*. 2009;30(6):1268–1276.
- [59]. Sieber MA. Pharmaceutical and safety aspects of gadolinium-based contrast agents. *EJHP Pract*. 2009;15(6):24–26.
- [60]. Staks T, Schuhmann-Giampieri G, Frenzel T, Weinmann HJ, Lange L, Platzek J. Pharmacokinetics, dose proportionality, and tolerability of gadobutrol after single intravenous injection in healthy volunteers. *Invest Radiol*. 1994;29(7):709–715.
- [61]. Stark DD, Weissleder R, Elizondo G, et al. Superparamagnetic iron oxide: clinical application as a contrast agent for MR imaging of the liver. *Radiology*. 1988;168(2):297–301.
- [62]. Steger-Hartmann T, Hofmeister R, Ernst R, Pietsch H, Sieber MA, Walter J. A review of preclinical safety data for magnevist (gadopentetate dimeglumine) in the context of nephrogenic systemic fibrosis. *Invest Radiol*. 2010;45(9):520–528.

- [63]. Steger-Hartmann T, Raschke M, Riefke B, Pietsch H, Sieber MA, Walter J. The involvement of pro-inflammatory cytokines in nephrogenic systemic fibrosis—a mechanistic hypothesis based on preclinical results from a rat model treated with gadodiamide. *Exp Toxicol Pathol.* 2009;61(6):537–552.
- [64]. Thomsen H, Morcos S, Almén T, et al. Nephrogenic systemic fibrosis and gadoliniumbased contrast media: updated ESUR Contrast Medium Safety Committee guidelines. *Eur Radiol.* 2013;23(2):307–318.
- [65]. Tombach B, Bremer C, Reimer P, et al. Pharmacokinetics of 1 M gadobutrol in patients with chronic renal failure. *Invest Radiol.* 2000;35(1):35–40.
- [66]. Voth M, Rosenberg M, Breuer J. Safety of gadobutrol, a new generation of contrast agents: experience from clinical trials and postmarketing surveillance. *Invest Radiol.* 2011;46(11):663–671.
- [67]. Wang Y, Alkasab TK, Narin O, et al. Incidence of nephrogenic systemic fibrosis after adoption of restrictive gadolinium-based contrast agent guidelines. *Radiology.* 2011;260(1):105–111.
- [68]. Weinmann HJ, Brasch RC, Press WR, Wesbey GE. Characteristics of gadolinium-DTPA complex: a potential NMR contrast agent. *AJR Am J Roentgenol.* 1984;142(3):619–624.
- [69]. Weinmann HJ, Laniado M, Mutzel W. Pharmacokinetics of GdDTPA/dimeglumine after intravenous injection into healthy volunteers. *Physiol Chem Phys Med NMR.* 1984;16(2):167–172.
- [70]. Young IR, Clarke GJ, Bailes DR, Pennock JM, Doyle FH, Bydder GM. Enhancement of relaxation rate with paramagnetic contrast agents in NMR imaging. *J Comput Tomogr.* 1981;5(6):543–547.

Sami S. Alshowiman." MRI Contrast Agents: Developments, Challenges, and Future Trends" International Journal of Pharmaceutical Science Invention(IJPSI), vol. 07, no. 04, 2018, pp. 11-22.