

## Healing Action of Passion Fruit and Pequi Creams on Induced Skin Lesions in Mice

<sup>1</sup>Eduardo Andrade Vasconcelos; <sup>2</sup>Esmeralda Maria Lustosa Barros; <sup>3</sup>Carla Cecília da Costa Almeida; <sup>4</sup>Larena Virna Guimarães Souza; <sup>5</sup>José Moacir Machado Neto; <sup>6</sup>Manuela de Sousa Moura Fé; <sup>7</sup>Sarah Izabelly Alves Lemos; <sup>8</sup>Kellyanne Soares de Sousa; <sup>9</sup>Marcello Alencar Silva

<sup>1, 3, 4, 5, 6, 8, 9</sup>(Faculdade Integral Diferencial / FACID-DEVRY, Brazil)

<sup>2, 7</sup>(Universidade Federal do Piauí / UFPI, Brazil)

Corresponding Author: Eduardo Andrade Vasconcelos

---

**Abstract:** The use of plants to treat various diseases is very common in Brazil. Passion fruit (*Passiflora edulis* Sims) and pequi (*Caryocar coriaceum* Wittm) are rich in antioxidants and vitamin A and used to treat skin infections and inflammations by presenting, among others, analgesic and anti-inflammatory properties. This study aims to analyze the repairing effect of *Passiflora edulis* and *Caryocar coriaceum* cream on the healing of cutaneous lesions in mice. The present work had approval number 01/16 and is in accordance with the provisions of Law 11794/2008, Decree No. 6.899 / 2009 and the National Council for the Control of Animal Experimentation (CONCEA). Fifty-six mice of the *Mus musculus* variety were randomly assigned to 4 groups of 6 animals treated with *Passiflora edulis*, Fibrinase® and saline. At the end of the 7 day and 14 day cycle, the mice were euthanized with a barbiturate overdose.

**Results:** There was a difference in favor of the healing of the experimental groups in relation to the control group in the 7th and 14th days regarding the reduction of inflammation.

**Conclusion:** It can be concluded that the treatment with passionflower cream (*Passiflora edulis*) and pequi (*Caryocar coriaceum*) was effective in the healing process in cutaneous lesions, but a broader study is needed to better understand the mechanisms involved.

**Keywords:** *Passiflora edulis* S., *Caryocar coriaceum* W., Skin lesion, Tissue repair

---

Date of Submission: 29-05-2017

Date of acceptance: 21-07-2017

---

### I. Introduction

The use of medicinal plants can be understood as a practice that crosses millennia, being historically present in the wisdom of common sense, articulating culture and health, since these aspects do not occur separately, but inserted in a determined historical context. Products of plant origin have, over the centuries, constituted the basis for treatment of various diseases, either in a traditional way, due to the knowledge of the properties of a given plant, which is passed from generation to generation, or by the use of plant species, source of active molecules [2].

In the wound healing process, the use of these products is not different, it has been mentioned since prehistory, when plants and plant extracts were used, in the form of cataplasms, in order to staunch hemorrhages and favor cicatrization, being many of these ingested plants, to act in a systemic way [3]. Hence, it is possible to state that medicine, as we know it today, was only possible by retrieving the methods of healing and empirical knowledge used for thousands of years. Thus, there are several resources available to aid in the healing process and its application in the dressing of wound dressings and techniques [5].

Throughout the last decades, researchers from several study centers have been investigating the use of different materials in order to overcome the deficiencies of the conventional treatment of cutaneous wounds. With the evolution of medicine, there were substances that had credit to help in the healing process. Some remained with this credit, others did not [6]. There is now a growing search for natural products for the treatment of various diseases, concomitantly with the development of new pharmaceutical forms and techniques for quality control. These facts have driven the research of new active substances based on popular knowledge [7].

Healing is the process by which an injured tissue is replaced by vascularized connective tissue. There is initially the installation of an inflammatory reaction whose exudate of phagocytic cells reabsorbs the extravasated blood and the products of tissue destruction. Then, the fibroblastic and endothelial proliferation

---

that forms the cicatricial connective tissue occur. Subsequently, the scar tissue undergoes remodeling, which results in a decrease in cicatricial volume, and may reach its disappearance [8].

Wound healing occurs in three phases or overlapping periods: initial phase, exudative or inflammatory phase, proliferative phase and remodeling or maturation phase. Each of these phases is characterized by the presence of cell infiltrates at specific sites, which occurs in an integrated manner and coordinated by chemical mediators, in order to optimize the repair. According to [9], the macroscopic characteristics of the stages of inflammation and debridement for an open wound include blood clot, serosanguinolytic exudate and granulation-free surface. The concentration of polymorphonuclear cells is high at the beginning of the inflammatory process and decreases with the evolution of healing [10]. During the formation of the new tissue, fibroblastic and angioblastic proliferation occur (angiogenesis) [11]; [12]; [9]; [13]. Thus, in general, the main parameter evaluated in wound healing in animal models is the reduction of wound size, usually expressed in terms of area. Histological analyses of granulation and epidermal tissue complement the evaluation [14]

According to [10], the first phase of healing aims to achieve hemostasis resulting from fibrin clot formation and migration of phagocytic leukocytes, which have the function of removing foreign substances and microorganisms. The second is characterized by the migration and proliferation of three cell classes: fibroblasts, endothelium and keratinocytes; Besides depositing fibronectin on the fibrin framework, forming fibronexus; Of the secretion of collagen III, mostly on the latter, and the synthesis of other matrix elements, the fibroblast being the main responsible for these structural changes. In the third and last phase, there is a change in the organization pattern of collagen and its main type, with collagen III being replaced by collagen I, increasing the number of crosslinks between the monomers of this substance and the prevalent orientation in the skin stress lines, phenomena which increase the strength of the wound.

Phytotherapy is a science that has as characteristic the study of the therapeutic action of medicinal plants and their different pharmaceutical forms, without the use of isolated active principles, although of vegetal origin. With this, it has the function of verifying the pharmacological action of many plants used in popular medicine, knowledge that is usually passed orally from generation to generation [14].

The therapeutic value of pequi ascribed to folk medicine has been researched and a wide variety of scientific experiments attest to its real effectiveness. In the oil extracted from the pulp were found natural antioxidants that decreased oxidative stress and, consequently, promoted protection against DNA damage [15]. The *Caryocar coriaceum* Wittm (pequi) is characterized by the drupe type, its globose shape, with yellowish-green bark and oil-rich mesocarp, presenting from one to four bulky seeds, whose woody endocarp protects them; This one has thin and acute thorns [16]. Vitamin A and a variety of fatty acids including oleic, palmitic, myristic, linolenic, palmitolytic, stearic and linoleic [17] have been observed as components of pequi oil. The latter is applied in the therapy and / or prevention of open cutaneous lesions, due to its bactericidal character, to increase the permeability of the cell membrane and to favor the entry of growth agents, besides promoting mitosis and cellular proliferation, to contribute to the genesis of new vessels and to favor leukocyte chemotaxis [5]. The pequi tree is a typical species of the Brazilian Cerrado, being, thus, peculiar to the Mid-West, North and part of the Northeast regions [18]. The species *Caryocar coriaceum* Wittm is used for various purposes, which encompasses use in culinary preparations as well as in the growing Cosmetics Industry [17]. The fruit is also indicated in folk medicine due to the anti-inflammatory and healing effects, being outstanding in the therapy of respiratory infections, gastric ulcers, rheumatic and muscular pains [16]. However, such effects need scientific proof [19].

Said fruit presents an important relevance for the health area, considering its possible therapeutic efficacy for the treatment of certain inflammatory processes. The macroscopic analysis and histopathological aspects of the evolution evidenced during the suggested therapy can corroborate, or even expose, adverse manifestations regarding the possible medicinal properties [20]. Passion flower (*Passiflora edulis* Smis) is widely used by the local population for various purposes, both as food and in folk medicine. The oil is extracted through pressing the pulp and the seed of the fruit and is used as food. Its medicinal use is broad in popular wisdom. It is also used in wounds and burns, having immediate effect on the relief of pain and aiding in the healing process. In the cosmetic industry, its effect was discovered as sunscreen. It also works as an efficient antioxidant, in addition to being rich in vitamin A, carotenoids and fatty acids [21].

*Passiflora edulis*, popularly known as passion fruit, is also called yellow passion fruit, rounded passion fruit, peroba passion fruit, purple passion fruit, little passion fruit, black passion fruit and garapa passion fruit. It is a species of climbing plant, originated in the tropical and subtropical regions of America, which belongs to the family Passifloraceae [21]. The species is cultivated in great quantity by the population, due to both its fruit and the beauty of its flowers. In this species various chemical substances can be found, such as alkaloids (harmana, harmina, harmalina and harmol), flavonoids and carotenoids. According to studies, it has sedative, analgesic, hypnotic, anti-inflammatory and parasympatholytic properties. The species is listed by the Ministry of Health as one of the plants that can be used as herbal medicines by the Unified Health System (SUS), mainly as a tranquilizer [22].

In the form of leaf infusion, it is used in cases of anxiety, epilepsy, insomnia, fever, headache, asthma, cough, abdominal pain and diarrhea. In Brazilian rural areas, the poultice made with *Passiflora edulis* leaves is used as medicine by the population to treat infections and cutaneous inflammations, however, this property has no scientific proof [23]. Regarding the analgesic and anti-inflammatory effects, which occur through the use of the extract of *Passiflora edulis* as teas or topically, the species presents characteristics of non-steroidal anti-inflammatory drugs (NSAIDs). These reduce pain due to the inhibition of the synthesis of eicosanoids, mediators of inflammatory processes, through the inhibitory action of the enzyme cyclooxygenase (COX), which transforms arachidonic acid into prostaglandins, prostacyclins and thromboxanes. It is known that anti-inflammatory agents favor healing, since exaggerated acute inflammation can reduce tissue blood supply and affect fibroblastic proliferation, they reduce collagenolysis in the first three days, and increase collagen production [24].

## II. Aims & Objectives

The objective of this study was to analyze the repairing effect of *Passiflora edulis* S. and *Caryocar coriaceum* W. cream on the healing of cutaneous lesions in mice. The specific objectives are to analyze the healing process through the morphometry of the cutaneous lesion area in different experimental groups, as well as to compare, through histological analysis, the healing process of cutaneous lesions induced in mice and treated with *Passiflora edulis* S. and *Caryocar coriaceum* W.

## III. Material And Methods

The research protocol was submitted to the Ethics Committee for the Use of Animals (CEUA / FACID), and approval number 01/16 was obtained, supported by the resolution of Law No. 11,794 of October 8, 2008. Decree n° 6.899, of July 15, 2009, and with the norms published by the National Council of Control of Animal Experimentation (CONCEA).

The research was of the descriptive experimental type with a qualitative approach, aiming to analyze the following variables: vascular proliferation, proliferation of fibroblasts, presence of inflammatory infiltrate, granulation tissue and re-epithelialization of wounds (histological analyzes) in mice investigated; And quantitative approach, aiming to analyze the reduction of the lesion area (morphometric analysis).

The fruit of pequi used for extraction of the oil used in this study was collected after the natural fall, in the municipality of Altos (PI). They were rinsed in manually stripped tap water, cooked at a temperature of about 60 ° C to 80 ° C for about 40 minutes. After this process the supernatant was collected, placed in another container and taken to the fire for complete dehydration. After cooling the obtained oil was packed in labeled amber container and stored in refrigerator for later use. The passion fruit leaves were also collected intact in the municipality of Altos (PI) and then left to dry for two weeks at room temperature. After this procedure, they were placed in a drying oven to remove moisture at a temperature of 45° to 50°C, for 24 hours. Then the leaves were ground in an industrial blender (METVISA–26FEB14), in the laboratory of the Faculdade Integral Diferencial, (FACID / DeVry), in Teresina - Piauí. After grinding it, a greenish colored powder was obtained, to which Absolute Ethyl Alcohol (99%) was added to extract the oil. The obtained mixture would be shaken manually for five minutes every two hours for 12 hours and filtered through a single glass funnel and cotton for three consecutive times. The ethanolic extract will be concentrated on a rotary evaporator (IKA RV-10) under reduced pressure and controlled temperature (50 ° C - 55 ° C). The resulting material will be stored in the refrigerator throughout the development. The extract obtained from passion fruit leaves (*Passiflora edulis* S) and the oil obtained from pequi were incorporated into an inert base (Lanete) at concentrations of 5% and 10% for each 100g (Figure 1)

**Figure 1:** Creams prepared with passion fruit and pequi extract, respectively.



Source: Personal Archive, 2016

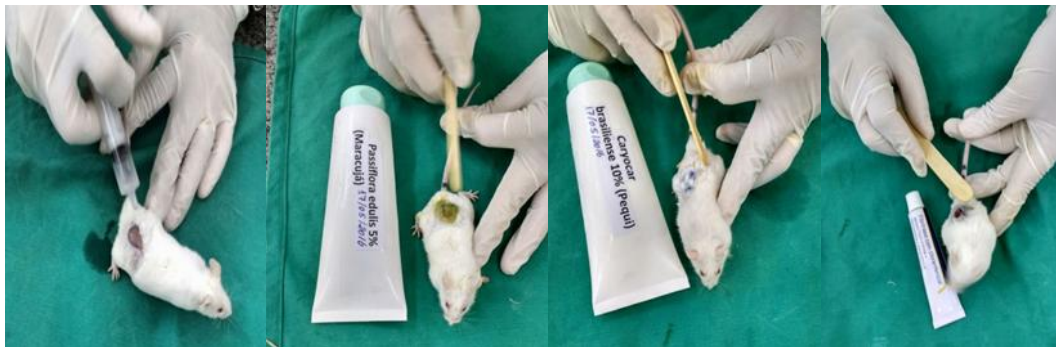The experiment was carried out with 56 adult animals, *Mus musculus*, weighing between 30g and 40g, clinically healthy, obtained in the FACID / DEVRY manger, kept in a light and dark environment of 12h, feed and water at will, kept at room temperature, between 24 and 25°C. They were randomly assigned to four experimental groups with 14 animals in each group, which corresponded to a different evaluation treatment, as follows:

- Positive control group (G1): formed by 14 mice with skin lesions and treated with fibrinase®.
- Passiflora group (passion fruit) 5% (G2): formed by fourteen mice with cutaneous lesions and treated with passion fruit cream at 5%
- Caryocar group (pequi) 10% (G3): formed by four mice with cutaneous lesions and treated at 10%
- Negative control group (G4): formed by four mice with cutaneous lesions treated with saline solution 0.9%.

For the experiment, the animals were weighed and sedated intramuscularly, with the combination of Ketamine (100mg / ml) and Xilazine (20mg / ml), at the volume dose 50µl per 100g body weight. After anesthesia, the animals were placed in the ventral decubitus position, performing a tricotomy of the dorsal region and proceeding with the local asepsis with povidone topical iodine solution. Under the exposed area a circular area of 0.8 mm diameter was delimited using a cast mold. Afterwards, the skin was excised through an incision and fleshy paniculus, respecting the due markings.

After hemostasis, the first topical administrations in the lesions were performed, with 0.5 g of pequi cream and 10% passion fruit, 0.5 ml of 0.9% Physiological solution and Fribrase® ointment in the respective groups. Subsequently, applications were performed every 24 hours respecting the schedules. (Figure 2).

**Figure 2:** Mice being treated with 0.9% physiological solution, 5% passion fruit cream, 10% pequi cream and fribrase®



Source: Personal Archive, 2016

On the 7th and 14th days of treatment, the animals were submitted to euthanasia with overdosage of anesthetic (Tiopental Sodium), aiming to withdraw tissue sample for histological analysis.

In order to determine the area of the lesion and its macroscopic aspects, were done the measurement and the digital photographic recording of the wound of all the animals of the groups, with position and standard height of 30 cm in the postoperative period, on Basal days, 7<sup>th</sup> and 14<sup>th</sup> of treatment. The image of the digital image of the lesion was imported into the Image J software to calculate regression of the lesion area of each animal

After euthanasia, each surgical lesion was dissected with a 1 cm margin of skin integrated into the lesion and placed in a vial containing 10% formalin. Soon after the pieces went through a routine laboratory process for inclusion in paraffin. The blocks were made in a rotating microtome with 0.5-micron longitudinal cuts and stained as hematoxylin-eosin (HE). The analysis was based on criteria of vascular and cell proliferation, polymorphonuclear or mononuclear infiltrates, proliferation of fibroblasts, deposition of collagen fibers and repitalization, a binocular optical microscope was used in the 40 X objective for cell differentiation.

The data were submitted to statistical analysis using the GraphPad Prisma 5.0 program by the ANOVA method followed by the Tukey test, with a confidence interval of 95% and  $p < 0.05$  or  $p < 0.001$ .

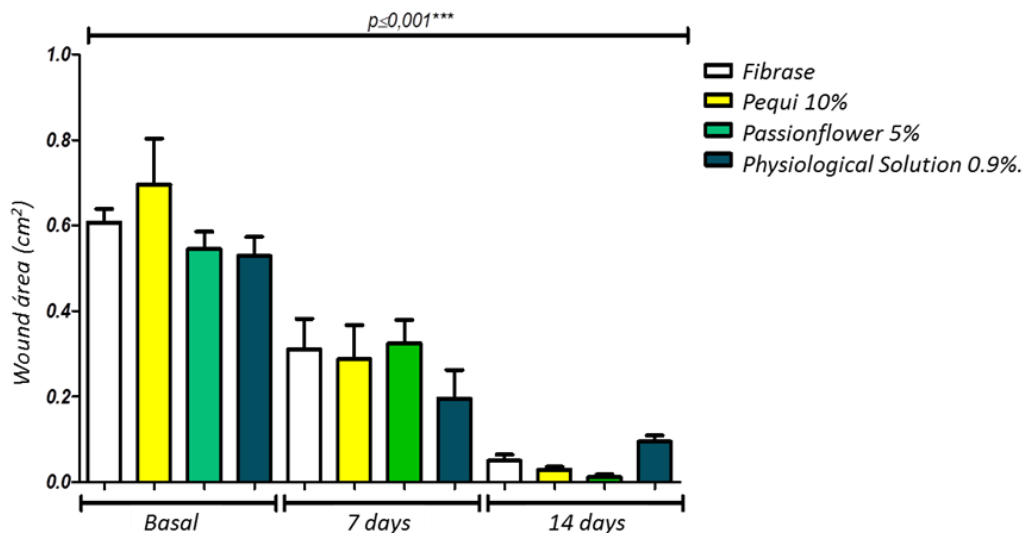
#### **IV. Results And Discussion**

In the morphometric evaluation of the healing process of the wound area (as can be seen on the y axis) in the basal (beginning) periods, 7 and 14 days. The comparison is within the group itself, it was compared and found that in all of them there was statistical significance of  $p < 0.001$ , that is, in all treatments the wound area decreased in both 7 and 14 days in all groups. (Graph - Figure 3).

No wound presented greater area than the initial one at the 7th and 14th postoperative days, the study verified that a reduction of the wound began on the 7th day and on the 14th they were already completely closed in the majority of the groups

In the comparison of the four groups there was no statistically better functional performance in the group that was treated with 5% passion fruit cream or 10% pequi cream. The negative control (0.9% physiological solution and the Fibrase® positive control group) (Graph - Figure 4).

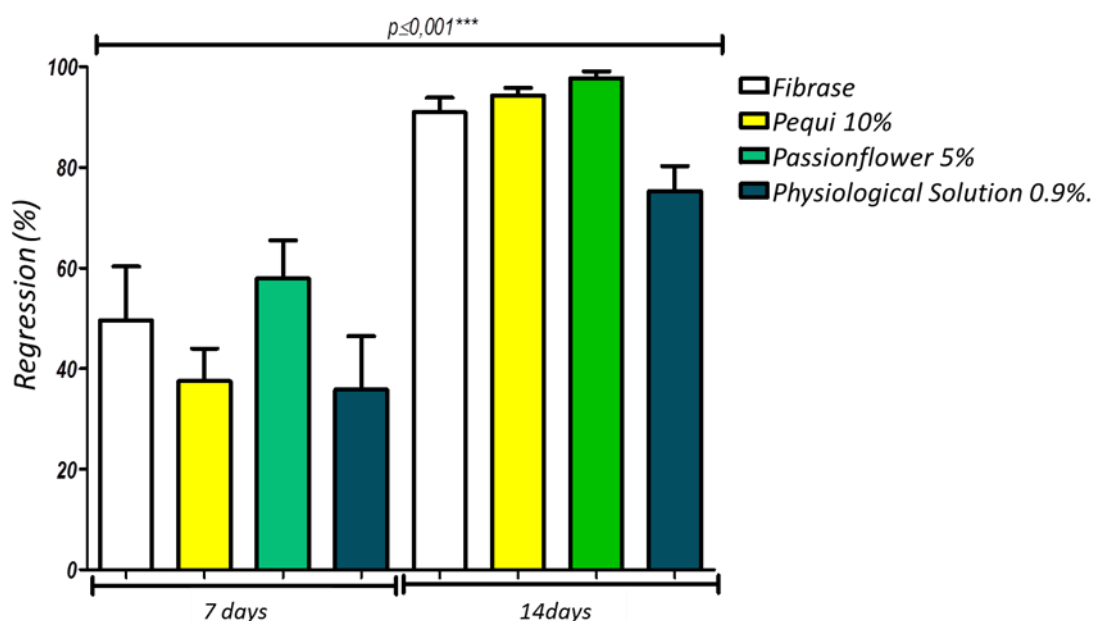
**Graph - Figure 3:** Evaluation of the area of cutaneous wounds in the groups of animals treated with Fibrase®, Pequi 10%, Passionflower 5% and physiological solution 0,9%.



Caption: p for unpaired One-Way ANOVA test, with 95% CI and significance at  $p < 0.05$ . Teresina, 2016.

In the comparison between the four groups, the percentage of wound regression was evaluated in the 4 treatments used in the research. It was observed that there was a statistically better functional performance in all the groups that were submitted to treatment with 5% passion fruit cream or cream of pequi to 10%. The negative control (0.9% physiological solution and the Fibrase® positive control group) (Graph - Figure 4).




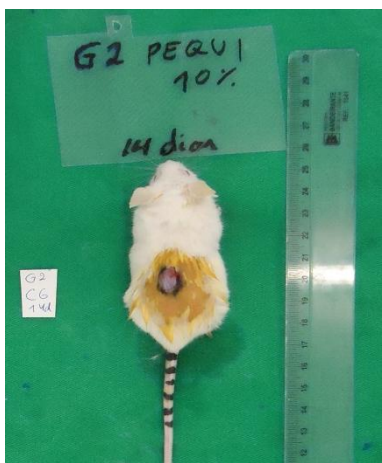
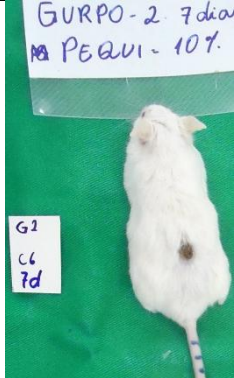



**Graph - Figure 4:** Evaluation of the regression of cutaneous wounds in the groups of animals treated with Fibrase®, Pequi 10%, Passionflower 5% and physiological solution 0,9%




Legend: p for unpaired One-Way ANOVA test, with 95% CI and significance at  $p < 0.05$ . Teresina, 2016.

*Healing Action of Passion Fruit and Pequi Creams on Induced Skin Lesions in Mice*

In the histological analysis of the lesions performed by means of microscopy, in the 7-day treatment period, a larger number of inflammatory cells, fibrins and other elements were observed in the negative control group, confirming the presence of an inflammatory process. Compared to the other groups where minor amounts of inflammatory cells were observed. As for the animals that underwent treatment for 14 days, it was possible to observe a reduction of the inflammatory process when the amount of fibroblasts present in all groups is related to what characterizes the normal tissue healing process. This fact shows that the treatment with passion fruit cream at 5% and pequi at 100% applied to the lesions induced on the back of the animals accelerated the healing process when compared to the animals of the negative control. (Table-Figure 5) as can be observed macroscopically. **Figure 5:** Microscopic evaluation and evolution of the lesions in each group of treatment

Groups	Treatment day 0	Treatment day 7	Treatment day 14
Group 1			
Group 2			
Group 3			



Source: Personal Archive, 2016.

## V. Conclusion

Based on the results obtained during the development of this study, it can be concluded that the treatment with passionfruit cream 5% (*Passiflora edulis*) and pequi 10% (*Caryocar coriaceum*) was effective in the healing activity in cutaneous lesions, But there is a need for a broader study to better understand the mechanisms involved

## References

- [1]. ALVIM, N.A.T. et al. O uso de plantas medicinais como recurso terapêutico: das influências da formação profissional às implicações éticas e legais de sua aplicabilidade como extensão da prática de cuidar realizada pela enfermeira. *Revista Latino-Americana de Enfermagem*, 14(3), 2006, 316-323.
- [2]. CARVALHO, A. C. B.; SILVEIRA, D. Drogas vegetais: uma antiga nova forma de utilização de plantas medicinais. *Brasília Médica*, 48(2), 2010, 219-237.
- [3]. SILVA, D.M.; MOCELIN, K.R. O cuidado de enfermagem ao cliente portador de feridas sob a ótica do cuidado transcultural. *Nursing (São Paulo)*, 9(105), 2007, 8188.
- [4]. AQUINO, D. et al. de. Nível de conhecimento sobre riscos e benefícios do uso de plantas medicinais e fitoterápicos de uma comunidade do recife - PE. *Revista de Enfermagem UFPE On Line*, 1(1), 2007, 107-110.
- [5]. MANDELBAUM, S. H.; DI SANTIS, E.P.; MANDELBAUM, M.H.S. Cicatrização: conceitos atuais e recursos auxiliares parte II. *Anais Brasileiros de Dermatologia*, 78(5), 2003, 525-542.

- [6]. MATERA, J. Ensaio da eficácia e de exequibilidade de uso do creme ou gaze impregnada com *Triticum vulgare* em feridas cutâneas. *Artigos Técnicos em Série da Schering-Plough Coopers, São Paulo*, 8, 2002, 1-7.
- [7]. BÜRGER, M.; GHEDINI, P.C.; DORIGONI, P.A. et al. Cicatrização de feridas cutâneas em ratos tratados com Pomada caseira à base de plantas medicinais. *Rev. Bras. Plantas Med.*, 5, 2003, 91-97.
- [8]. PARENTE, LML; SILVA, MSB; BRITO, LAB; LINO-JÚNIOR, RS; PAULA, JR; TREVENZOL, L. MF. Efeito cicatrizante e atividade antibacteriana da *Calendula officinalis* L. cultivada no Brasil. *Revista Brasileira Plantas Medicinais*. 11(4), 2009, 383-391.
- [9]. HOSGOOD, G. Stages of wound healing and their clinical relevance. *Veterinary Clinics: Small Animal Practice*, 36, 2006, 667-85.
- [10]. SANCHEZ NETO, R. et al. Aspectos morfológicos e morfométricos da reparação tecidual de feridas cutâneas de ratos com e sem tratamento com solução de papaína a 2 por cento. *Acta Cirúrgica Brasileira*, 8(1), 1993, 18-23.
- [11]. CASTELO BRANCO NETO, M.L. et al. Avaliação do extrato hidroalcoólico de Aroeira (*Shinus terebinthifolius* Raddi) no processo de cicatrização de feridas em pele de ratos. *Acta Cirúrgica Brasileira*, 21(2), 2006, 17-22.
- [12]. DE NARDI, A.B. et al. Cicatrização secundária de feridas dermoepidérmicas tratadas com ácidos graxos essenciais, vitamina A e E, lecitina de soja e iodo polivinilpirrolidona em cães. *Archives of Veterinary Science*, 9(1), 2004, 1-16.
- [13]. RUBIN, E. et al. Patologia: bases citopatológicas da medicina. 4.ed. Rio de Janeiro: Guanabara Koogan, 2006.
- [14]. KRISHNAN, P. The scientific study of herbal wound healing therapies: Current state of play. *Current Anaesthesia & Critical Care*, 17(1-2), 2006, 21-27.
- [15]. MIRANDA-VILELA, A.L.; RESCK, I.S.; GRISOLIA, C.K. Antigenotoxic activity and antioxidant properties of organic and aqueous extracts of pequi fruit (*Caryocar brasiliense* Camb.) pulp. *Genetics and Molecular Biology*, 31, 2008, 956-963.
- [16]. MATOS, F. J. A. Plantas medicinais: guia de seleção e emprego de plantas usadas em fitoterapia no Nordeste do Brasil, 3ª edição *Imprensa Universitária. Fortaleza, Brasil*, p. 394, 2007.
- [17]. PIANOVSKI, A.R.; VILELA, A.F.G.; SILVA, A.A.S.; LIMA, C.G.; SILVA, K.K.; CARVALHO, V.F.M.; MUSIS, C.R.; MACHADO, S.R.P.; FERRARI, M. Uso do óleo de pequi (*Caryocar brasiliense*) em emulsões cosméticas: desenvolvimento e avaliação da estabilidade física. *Revista Brasileira de Ciências Farmacêuticas*, 44(2), 2008, 249-259.
- [18]. OLIVEIRA, M.N.S.; GUSMÃO, E.; LOPES, P.S.N.; SI-MÔES, M.O.M.; RIBEIRO, L.M.; DIAS, B.A.S. Estádio de maturação dos frutos e fatores relacionados o aspectos nutritivos e de textura da polpa de pequi (*Caryocar brasiliense* Camb.). *Revista Brasileira de Fruticultura*, 28(3), 2006, 380-386.
- [19]. BEZERRA, NKMS; BARROS, T. L.; COELHO, NPMF. The effect of the Pequi oil (*Caryocar brasiliense*) in the healing of skin lesions in mice. *Revista Brasileira de Plantas Medicinais*, 17(4), 2015, 875-880.
- [20]. BATISTA, J. S. et al. Avaliação da atividade cicatrizante do óleo de pequi (*caryocar coriaceum* wittm) em feridas cutâneas produzidas experimentalmente em ratos. *Arq. Inst. Biol., São Paulo*, 77( 3), 2010, 441-447.
- [21]. GONCALVES FILHO, Antonio et al . Efeito do extrato de *Passiflora edulis* (maracujá) na cicatrização de bexiga em ratos: estudo morfológico. *Acta Cir. Bras.*, São Paulo, 21( 2), 2006, 3-8.
- [22]. BEZERRA, José Antonio Ferreira et al . Extrato de *Passiflora edulis* na cicatrização de anastomose colônica em ratos: estudo morfológico e tensiométrico. *Acta Cir. Bras.*, São Paulo, 21(3), 2006, 16-25.
- [23]. GARROS, I. C.; CAMPOS, A. C. L.; TÂMBARA, E. M.; TENÓRIO, S. B.; TORRES, O. J. M.; AGULHAM, M. A.; ARAÚJO, A. C. F.; SANTIS-ISOLAN, P. M. B.; OLIVEIRA, R. M.; ARRUDA, E. C. M. Extrato de *Passiflora edulis* na cicatrização de feridas cutâneas abertas em ratos: estudo morfológico e histológico. *Acta Cirúrgica Brasileira, São Paulo*, 21(3), 2006.
- [24]. SILVA, José Ribamar Sousa da et al . Efeito do extrato da *Passiflora edulis* na cicatrização de gastrorrafias em ratos: estudo morfológico e tensiométrico. *Acta Cir. Bras.*, São Paulo, 21(2), 2006, 52-60.

Eduardo Andrade Vasconcelos. "Healing Action of Passion Fruit and Pequi Creams on Induced Skin Lesions in Mice." *International Journal of Pharmaceutical Science Invention(IJPSI)* 6.7 (2017): 36-43.