

A Variety of Anatomical and Clinical Manifestations of Myelinated Retinal Nerve Fibers

G. Dimitrova, B. Mihaylova, V. Chernodrinska

Department of Ophthalmology, Medical University, „Alexandrovska” Hospital, Sofia, Bulgaria

Abstract

Introduction: Myelinated Retinal Nerve Fibers (MRNF) represent a developmental anomaly that occurs in about 1% of the population. They appear as different in size, well demarcated white striated lesions along the retinal nerve fibers mainly in contiguity with the optic nerve head. The MRNF may be an isolated asymptomatic finding or associated with other ocular or systemic abnormalities, causing mild to significant visual loss.

Purpose: To present a variety of anatomical and clinical manifestations of MRNF.

Patients and methods: Between 2011 and 2016 nine patients (six children and three adults) with MRNF were admitted to the Eye clinic of the University Alexandrovska hospital in Sofia, Bulgaria. Full orthoptic and ophthalmologic examination was performed.

Results: Eight patients had unilateral MRNF, seven with the left eye and one - with the right eye involved. Two of them had the triad of MRNF, axial myopia and amblyopia (Straatsma syndrome). One patient had bilateral MRNF and hyperopia („reverse” Straatsma syndrome). Two adult patients were asymptomatic. The rest had a substantial visual impairment because of anisometropia, strabismus or massive myelinated lesions.

Conclusion: There is a great variety of anatomical and clinical manifestations of MRNF and their effect on the visual function depends on both organic and amblyogenic factors.

Keywords: myelinated retinal nerve fibers, optic disc hypoplasia, amblyogenic factors.

I. Introduction

In 1856 the German pathologist Rudolf Virchow [1] first described myelinated retinal nerve fibers (MRNF) as „thick, opaque, chalk-white spots, which spread around the disc in the shape of a star”. This developmental anomaly occurs in about 1% of the population. It may be asymptomatic and thus discovered incidentally during ophthalmic examination. However, affected eyes may have various degree of decreased visual acuity to significant visual loss and be associated with other ocular and systemic findings - retinal vascular abnormalities [2, 3], retinal membrane abnormalities[4], ocular developmental abnormalities, cranioccephalic abnormalities[5], and systemic hamartoneoplastic disorders [6]. Plagues are most often unilateral, but could be bilateral, may be congenital or acquired [7, 8], might progress or regress [9, 10,11], be associated with mild hyperopia, emetropia or myopia and strabismus. Triad of MRNF, axial myopia and amblyopia is known as Straatsma syndrome [12]. MRNF associated with farsightedness, strabismus and amblyopia has been described as a reverse Straatsma syndrome [13].

Our purpose is to demonstrate various anatomical and clinical manifestations of MRNF.

II. Patients and Methods

We presented a case series of nine patients (six children and three adults) seen at the Eye clinic of the University Alexandrovska hospital in Sofia, Bulgaria, between 2011 and 2016. The age ranged from 16 months to 74 years with female predominance (six females and three males).

All of them underwent full ophthalmologic and orthoptic examination - visual acuity or fixation, red reflex test, slit-lamp examination, funduscopy, cycloplegic refraction, binocular vision and ocular motility examination, PlusoptiX A12Cand retcamrecording (RetCam₃)in small children, spectral-domain optical coherence tomography (SD-OCT) with Topcon 3D OCT 2000+ (retinal nerve fiber layer - RNFLreport and line report) and standard automated perimetry-SAP (HFA II, Carl Zeiss Meditec) in adults.

III. Results

Eight patients had unilateral MRNF and in seven of them it was the left eye affected. Only one patient had bilateral MRNF. Ipsilateral axial myopia was observed in two patients who had anisometropia of 18.0 D and respectively of 12.0 D. In four patients one eye had hyperopia and the other - myopia with anisometropia of up to 4.0 D with MRNF being in the myopic eye. The patient with the bilateral MRNFhad hyperopia and anisometropia of 5.5 D with more affected disc in the more hyperopic eye. Two adult female patients did not have anisometropia. One of them was pseudophakic. Strabismus was documented in five patients: constant

esotropia in two, intermittent esotropia- in one and intermittent exotropia in two patients. The cases presentation is summarized in Table I.

Table I. Case series with MRNF.

Patients	Gender	Age at first exam	Affected with MRNF eye	Refraction Right eye - RE Left eye - LE	Anisometropia	Strabismus	Other ocular disease	Visual acuity
1	female	16 months	left eye	RE: +1,25 + 0,5/95 LE: - 17,0-0,75/166	18.0 D	XT	no	
2	female	7 years	left eye	RE: +1,5+0,5/106 LE: -0,25-0,5/133	1.0 D	no	no	0.07
3	female	18 months	left eye	RE:+1,0+0,5/68 LE: -3,25+1,5/99	3.0 D	ET	no	
4	male	2 years	left eye	RE: +2,5 LE: -1,5 -0,5/35	4.0 D	ET	no	
5	male	3 years	left eye	RE: +1,25 + 0,5/178 LE: -10,75-0,5/147	12.0 D	ET	no	0.05
6	female	15 months	left eye	RE: +1,5+0,75/85 LE: -2,5	4.0 D	XT	no	
7	male	19 years	bilateral	RE: +0,75+0,75/88 LE: +5,5+1,75/113	5.5D	no		0.9 0.08
8	female	69 years	left	RE: -2,0 LE: -2,5	0.5 D	no		0.9 0.8
9	female	74 years	right	RE: + 0,25 LE: +0,75	No	no	Cat op.	0.8 0.9

Extensive myelination, surrounding the whole disc was seen in three patients. This anatomical finding could explain the severe visual impairment and the intolerance to occlusion therapy, especially when the fibers nearly reached the macula (Fig.1). Patient 3 and 4, on the other hand, had esotropia of the affected eye and moderate anisometropia of 3.0-4.0 D. Their poor fixation behavior with resistance to amblyopia treatment had both anatomical and amblyogenic causes (Table 1).

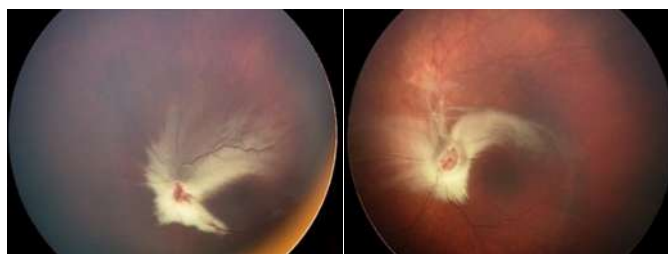

Fig. 1. Extensive myelination, involving the whole optic nerve head - patients 2 (left) and 4 (right). Retacam fundus images.

Patient 1 and 5 in Table 1 represented the Straatsma syndrome- a triad of MRNF, axial myopia and amblyopia (Fig.2). The two patients differed in genders, types of myelination and macular involvement, one had esotropia and the other-exotropia. Both had axial myopia in the affected left eyes, anisometropia of more than 10.0 D and severe amblyopia, with no improvement of visual acuity from occlusion therapy.

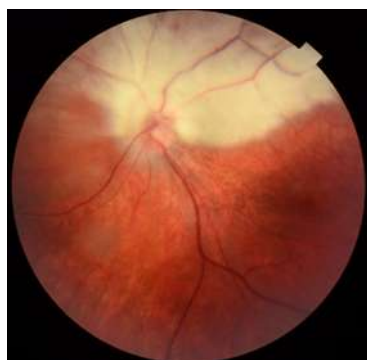


Fig. 2. Straatsma syndrome in Patients 5. Retacam fundus image.

Unlike the majority of congenital cases with unilateral impairment and myopic shift in the affected eyes, patient 7 had bilateral MRNF, hyperopia and anisometropia of about 5.0 D, the amblyopic eye being the left one with the higher hyperopia and more extensive myelination- what is known in literature as reverse Straatsma syndrome [13] (Table 1; Fig. 3). OCT line report through the optic nerve head (ONH) showed hyperreflection and abnormally thicker RNFL in both eyes.

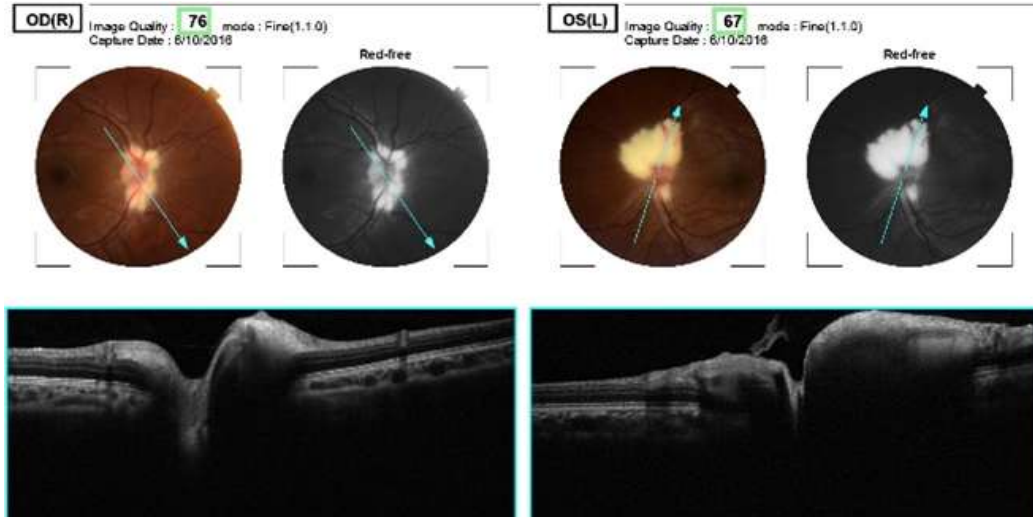


Fig. 3. Patient 7 with bilateral MRNF and OCT line report through the ONH.

In patient 6 there were slight myelinations along the arcades not contiguous with the ONH and noninvolvement of the macula (Table 1). This patient responded well to occlusion therapy in the presence of 4.0 D anisometropia and exotropia.

The two adult patients (8 and 9) were nearly asymptomatic (Table 1; Fig. 4 and 5). The MRNF were diagnosed in the course of an eye examination and were documented on OCT fundus camera. The abnormally increased peripapillary RNFL thickness was measured with circumpapillary B-scan in superior quadrant corresponding to the location of the lesion (see the arrows in Circle protocol - Fig. 4, left). The fundus autofluorescence (FAF) demonstrated hyporeflection in the area of MRNF above the ONH (Fig. 4 - right). OCT line report through the MRNF in patient 9 showed hyperreflection of RNFL and hyporeflection of the structures below (Fig. 5 - left) and visual field defect on the SAP, corresponding to the lesion in the affected eye. Patient 9 was the oldest one in the series and we could speculate this sector myelination, not contiguous with the ONH, was acquired for it looked different from the other cases.

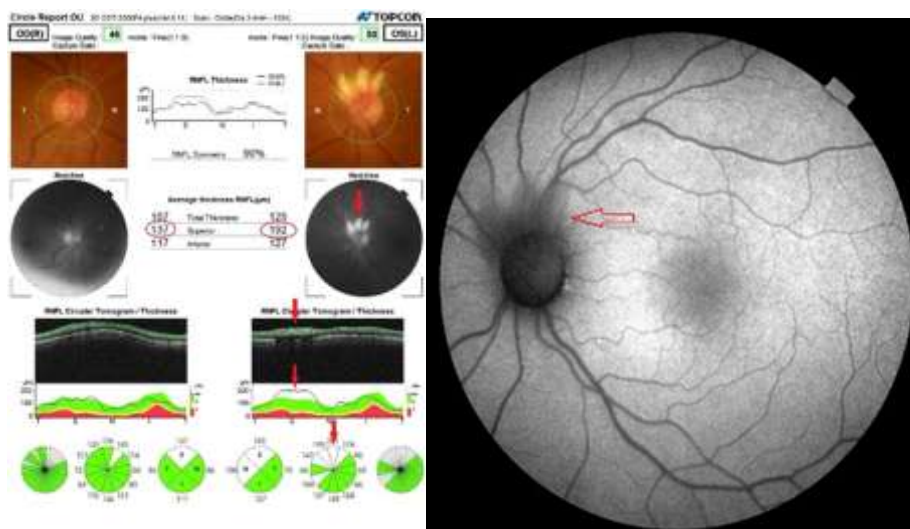


Fig. 4. Patient 8 – OCT: RNFL thickness protocol (left) and FAF (right).

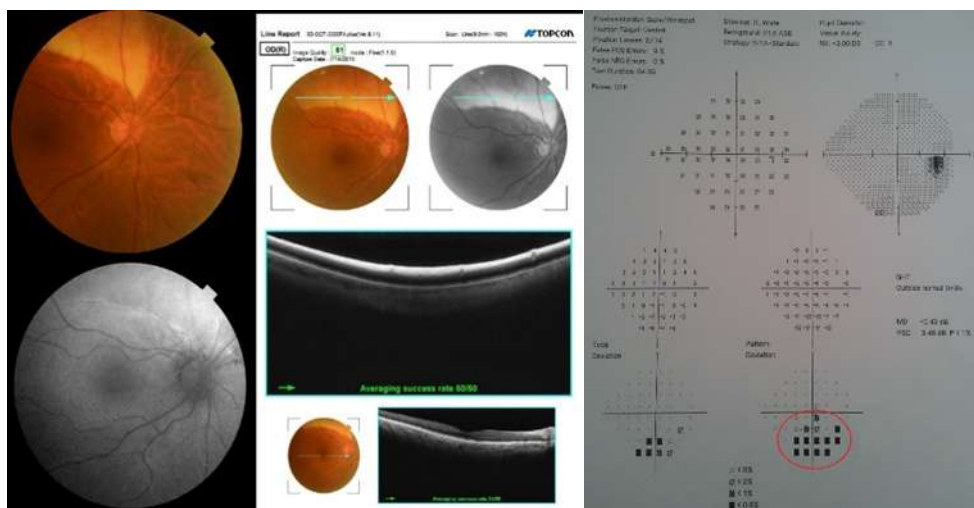


Fig. 5. Patient 9 - OCT (Line report and fundus images) and SAP of the right eye.

IV. Discussion

We presented nine patients with a variety of anatomical and clinical manifestations of MRNF. All but one case were unilateral and majority of the affected eyes were the left eyes. Some authors reported no statistical difference between males and females, others found male predominance [5]. In our case series there were more females than males with MRNF.

The refraction of the affected eyes was myopic in all cases from the children's group with a different degree of anisometropia (Table I). Two of our cases had a triad of axial myopia, severe anisometropia and amblyopia. In 1976 Holland and Anderson [14] first associated myelinated nerve fibers with excessive myopia, but it was Straatsma et al., who in 1979 reported 4 cases with extensive unilateral MRNF, ipsilateral axial myopia and amblyopia and estimated the prevalence of this triad to be 10% - a syndrome, which was named after Straatsma [12]. In 1987 Ellis et al. further analyzed 6 patients with this syndrome, suggesting that low vision in these patients had both organic and functional etiology [15]. The authors found that 83% of patients with MRNF had myopia greater than 6 diopters. It was possible that myelination was the reason for myopia or visa-versa - it was the result of myopia. In 2007 Tarabishy et al. [16] made a detailed review on this syndrome and reported 11 patients, 3 of them had also ONH dysplasia. Another case report on the triad of MRNF, axial myopia and amblyopia was done in 2009 by Moradian and Karimi [17].

It was known MRNF to be more common in myopic than in hyperopic eyes, but there were some reports of myelinated fibers associated with hyperopia [18,19]. We also found that myopia was a more common refraction error in the MRNF eye. One case in our adult group had a reverse Straatsma syndrome- bilateral MRNF and untreated amblyopia in the more hyperopic eye.

The pathogenesis of MRNF remains not quite certain. Authors suggest that MRNF result from the anomalous retinal location of oligodendrocyte-like cells prior to development or temporary loss of the barrier function of the lamina cribrosa [16]. The myelination process normally terminates at the level of lamina cribrosa, but occasionally it continues into the retinal nerve fiber layer. Three different types of myelination are known - type 1 along the superior temporal arcade, type 2 along both the arcades and type 3 with no contiguity with the ONH. Majority of our cases had type 2 myelination.

Kee and Hwang [20] found that the prognostic factors for the visual improvement in amblyopia were the amount of anisometropia and the area of myelination. Other authors found similar trend of better vision in less anisometropia, although many patients suffered poor vision because of organic or structural abnormalities [16]-dysplastic-appearing optic nerves or abnormal foveal reflex. We also had a case with extensive myelination and hypoplastic appearance of the ONH, with no strabismus and nearly no anisometropia. Thus the poor visual performance was entirely due to the anatomic factor.

Along with anisometropia, strabismus was another amblyogenic factor which was associated with worse visual outcome. Five out of six patients in our children group had a squint- three had esotropia and two-exotropia. We don't support the dominance of exotropia in MRNF, established by some authors [17].

V. Conclusion

We presented nine patients with a variety of anatomical and clinical manifestations of MRNF- type 1, 2 and 3 myelinations, involving or not the optic disc and macula, with mild to substantial anisometropia, with or without strabismus, with myopic or hyperopic refraction in the affected eye, Straatsma or reverse Straatsma syndrome. Majority of cases were congenital, unilateral (mainly the left eye affected), non-progressive, with a

myopic shift and anisometropia. Noone from the case group had any systemic disorder.

Our analysis proved that the effect of MRNF on visual function depended on both organic and amblyogenic factors- the area of myelination, the appearance of the disc and macula, the degree of amblyopia and the presence or absence of strabismus.

References

- [1]. Virchow VR. Zur pathologischen Anatomie der Netzhaut und des Scherens. Virchows Arch Pathol Anat 1856; 10:170-93.
- [2]. Leys AM, Leys MJ, Mooymans JM, et al. Myelinated nerve fibers and retinal vascular abnormalities. Retina 1996; 16:89-96.
- [3]. Silvestri G, Sehmi K, Hamilton P. Retinal vascular abnormalities. A rare complication of myelinated nerve fibers? Retina 1996; 16:214-8.
- [4]. Hubbard GB, Thomas MA, Grossniklaus HE. Vitreomacular traction syndrome with extensively myelinated nerve fibers. Arch Ophthalmol 2002; 120(5):670-1.
- [5]. Straatsma BR, Foss BY, Heckenlively JR, Taylor GN. Myelinated retinal nerve fibers. Am J Ophthalmol 1981; 91:25-38.
- [6]. Parulekar MV, Elston JS. Acquired retinal myelination in neurofibromatosis. Arch Ophthalmol 2002; 120: 659-61.
- [7]. Aaby AA, Kushner BJ. Acquired and progressive myelinated nerve fibers. Arch Ophthalmol 1985; 103:542-4.
- [8]. Baarsma GS. Acquired medullated nerve fibers. Br J Ophthalmol 1980; 64:651.
- [9]. Ali B, Logani S, Kozlov K, et al. Progression of retinal nerve fiber myelination in childhood. Am J Ophthalmol 1994; 118:515-7.
- [10]. Lopez Sanchez E, et al. A case of loss of retinal myelinated nerve fibers in a chronic glaucoma. Archivos de la Sociedad Espanola de Oftalmologia 2002; 77:39-42.
- [11]. Mashayekhi A, Shields CL, Shields JA. Disappearance of retinal myelinated nerve fibers after plaque radiotherapy for choroidal melanoma. Retina 2003; 23:572-3.
- [12]. Straatsma BR, Heckenlively JR, Foos RY, Shahinian JK. Myelinated retinal nerve fibers associated with ipsilateral myopia, amblyopia, and strabismus. Am J Ophthalmol 1979; 88:506-10.
- [13]. Wang Y, Gonzalez C. Unilateral myelinated nerve fibers associated with hyperopia, strabismus and amblyopia. Reverse Straatsma syndrome? Binocul Vis Strabismus Q. 2008; 23:235-7.
- [14]. Holland PM, Anderson BJr. Myelinated nerve fibers and severe myopia. Am J Ophthalmol 1976; 81:597-99.
- [15]. Ellis GS, Jr, Frey T, Gouterman RZ. Myelinated nerve fibers, axial myopia, and refractory amblyopia: An organic disease. J Pediatr Ophthalmol 1987; 24:111-9.
- [16]. Tarabishy AB, Alexandrou TJ, Traboulsi EI. Syndrome of myelinated retinal nerve fibers, myopia and amblyopia: A review. Survey of Ophthalmol 2007; 52(6):588-96.
- [17]. Moradian S, Karimi S. Unilateral myelinated retinal nerve fiber layer associated with axial myopia, amblyopia and strabismus. Journal of Ophthalmic and Vision Research, 2009;(4)4: 264-5.
- [18]. Lee JS, Daniel SJ. Myelinated retinal nerve fibers associated with hyperopia and amblyopia. JAAPOS, 2008; 12: 418-9.
- [19]. Shenoy R, Bialasiewicz AA, Barwani BA. Bilateral hypermetropia, myelinated retinal nerve fibers and amblyopia. Middle East Afr J Ophthalmol., Jan-Mar, 2011; 18(1):65-66.
- [20]. Kee C, Hwang JM. Visual prognosis of amblyopia associated with myelinated retinal nerve fibers. Am J Ophthalmol 2005; 139:259-65.