

## Furunculomyiasis in a Child Caused by Flesh Fly (*Wohlfahrtiamagnifica*) and Associated Bacterial Infections

Mailafia, S<sup>1</sup>, Onakpa, M.M.<sup>2</sup>, and Simon, M.K<sup>3</sup>

<sup>1</sup>Department of Veterinary Microbiology, Faculty of Veterinary Medicine, University of Abuja, PMB 117, Abuja, Nigeria

<sup>2</sup>Department of Veterinary Pharmacology and Toxicology, Faculty of Veterinary Medicine, University of Abuja, PMB 117, Abuja, Nigeria

<sup>3</sup>Department of Veterinary Parasitology and Entomology, Faculty of Veterinary Medicine, University of Abuja, PMB 117, Abuja, Nigeria

---

**Abstract:** We report the case of a two-year-old boy with hypereosinophilia who presented with a swelling on his left scapular that had persisted for more than three weeks. A second-stage larva of *Wohlfahrtiamagnifica* was found with associated bacterial organisms such as *Proteus vulgaris*, *Staphylococcus aureus* and *Staphylococcus epidermidis*, leading to the diagnosis of cutaneous myiasis. Following removal of the larva and secondary bacterial therapy, the clinical and hematological manifestations returned to normal. Diagnosis of myiasis and associated secondary infections should always be kept in mind in the event of clinical signs of furuncular lesions, pain, fever, exudation which may be accompanied by eosinophilia.

**Keywords:** cutaneous myiasis, *Wohlfahrtiamagnifica*, Secondary bacteria, infections, pus

---

### I. Introduction

Myiasis, from the Greek *myia* for “fly,” has been defined as the infestation of live human or vertebrate animals with larvae of the insect order Diptera of the genera *Sarcophagidae*. It is usually classified from an entomological or clinical point of view. Entomologically flies may be classified into three myiasis producing groups; obligate, facultative and accidental. Clinically myiasis can be according to the organ that is affected (1,3). Myiasis is classified as furuncular, wound, gastrointestinal, urogenital, ocular, nasal or auricular (3,4,8 and 20). One of the most common forms of human myiasis is furuncular myiasis, which is the result of subcutaneous infestation by fly larvae. *Wohlfahrtiamagnifica* is an obligatory myiasis agent, which infests only the living tissue of animals and man. These larvae usually infest the ears, eyes, and nose, as well as healthy or damaged skin. In Turkey, *W. magnifica* has been reported as the cause of otomyiasis, orotracheal myiasis and wound myiasis (1,4).

The myiasis identified in our report is known to be complicated by secondary bacterial organisms which invade the infested areas leading to pain, pus formation, fever, and other cardinal signs of inflammation (11). The presence of *Staphylococcus aureus* alongside *Staphylococcus epidermidis* is connected to its ubiquitous nature and high affinity for residency on the skin (1); thereby causing the purulent infections indicated in our case report. Associated bacterial organisms include *Staphylococcus* species, *Streptococcus* species, *Micrococcus* species, *Pseudomonas* species, *Proteus* species and *Aeromonas* species. These organisms are capable of causing numerous diseases including: skin abscesses, pneumonia, fever, wound infections, gangrene, and intoxication and hypersensitivity reactions (2). In the present study, we report a case of furuncular myiasis caused by *W. magnifica* in a child who presented with significant blood eosinophilia, axilla lymphadenopathy and swelling/exudation over the left scapular muscle.

### II. Case Report

A previously healthy two-year-old boy living in Gwagwalada, Abuja, Nigeria was presented in June 2015 with a history of swelling on his left scapular muscle that had persisted for more than three weeks. His mother narrated that while attempting to extract pus from the lesion a larva was removed from the center of the furuncle and later identified as a second-stage larva of *W. magnifica* (Fig.1). Swap sample were aseptically collected from the pus and were subjected to standard laboratory culture and complete biochemical studies using Microbact™ oxid identification system based on the methods (2, 5). The culture results revealed three bacterial species which included: *Proteus vulgaris*, *Staphylococcus aureus* and *Staphylococcus epidermidis*. Histological examination shows a small cavity in the dermis where the larvae was removed. Around the cavity are heavy infiltration of mixed inflammatory cells, which include lymphocyte, histiocytes, occasional giant cells and plasma cells.

On clinical examination, the child was found to be mentally alert and hemodynamically stable. He had lymphadenopathies and swelling measuring about 2 cm in diameter in the axilla region and the swelling

extending from the right axilla to the chest region. The laboratory examinations showed a white blood cell count of 8,600 cells/mm<sup>3</sup> (with an absolute eosinophil count of 5,160 cells/mm<sup>3</sup>), hemoglobin 12.9 g/dl and platelets 254,000/mm<sup>3</sup>. The patient had normal serum IgG, IgA, and IgM levels but a high IgE level of 667 IU/ml. Direct parasitological investigations of stool and serological examinations for *Toxocara* species, *Fasciola hepatica* and *Echinococcus* species and their larvae were all negative. Following removal of the larva and treatment with penicillin-streptomycin combination at 1000 I.U./ml, for five days, the swelling over the right pectoral muscle and the axillary lymphadenopathies regressed rapidly. Serum IgE levels gradually decreased to 512 IU/ml, 307 IU/ml, 201 IU/ml and 182 IU/ml after 1, 2, and 4 weeks and 2 months, respectively. Absolute eosinophil count decreased to 1,360/mm<sup>3</sup> (3) after one week and to 480 cells/mm<sup>3</sup> one month later.

### III. Discussion

Myiasis due to *W. magnifica* is very rare in childhood. A few cases of wound (9), auricular (18) and ophthalmomyiasis (2, 13) have been reported. In the *Calliphoridae* and *Sarcophagidae*, most species that cause myiasis deposit their eggs or larvae directly onto the host at some predisposing site, such as those caused by wounding, necrosis or bacterial contamination (7). Healthy hosts are much less attractive, even for obligate species such as *W. magnifica*, which can attack healthy tissue. Advanced age, poor social conditions, mental retardation, immobilization, diabetes mellitus, alcoholism, vascular occlusive disease, and infected dermatitis complicated by bacterial infections are predisposing factors for cutaneous myiasis (3, 10).

The predisposing factors indicated in our study included close contact with dogs in the outdoors and probably from drying laundry outdoors which exposes the clothes to flies as soon as the sun sets and the clothes are not immediately removed. The possible presence of microorganisms associated with the pus lesions in our case may be due to bacterial invasiveness in which the presence of larvae may draw the microorganisms to sites of braided lesion thereby causing pus formation as observed in our studies. The flesh and skin of humans also provides conducive temperature for the growth of most of these isolated bacterial organisms. More so, the metabolites from the larvae may provide carbon source for microbial biosynthesis, thereby aiding the proliferation of the bacteria at the site of lesion. The presence of these microorganisms indicated in our case report may further lead to serious health challenge such as skin abscesses, necrosis, fever, pneumonia, gangrene, and many others had it been the case has not been arrested early enough. Our report professes a signal for public health authorities in Nigeria to be strengthened and more cases of this nature be reported to relevant authorities to minimize the scourge of myiasis.

Infestation of mammals such as cows, horses, goats, sheep, pigs and dogs is not uncommon (11). It seems probable that the eggs of larvae of the flesh fly migrated from dogs from neighborhood via aerosol or contact to our patient from his clothes which were sun dried after laundry but were not removed even after sunset. Another possibility could be through contact while the child plays with dogs around the neighborhood. The eggs may find lodgment to the skin thereby especially at night hours at ambient heat while the child sleeps, thereby hatching to larvae which immediately penetrates the soft skin and lodge in the flesh (11, 12).

In furuncular myiasis, a pruritic papule of approximately 2 to 3 mm in diameter develops within 24 hours of initial infestation by the larva and associated microorganisms. The patient may feel pain caused by the bacterial infection and tearing of the tissue caused by the feeding and movement of the larvae (12). Only one or a few larvae are usually present in furunculoid whereas many larvae commonly occur in wounds and cavities. Our patient had only one larva and he rapidly healed following its removal following secondary bacterial therapy. The clinical pattern depends on the species of fly and location of the infestation. Marked inflammatory reactions and bacterial pruritus, massive destruction and life-threatening outcomes, such as intracranial invasion, can be caused by myiasis.

Analysis of tissues exhibiting an inflammatory response to maggot infestation revealed a high concentration of lymphocytes, giant cells, neutrophils, eosinophils and plasma cells (13). Helminthic parasites and allergies are the most common cause of eosinophilia, while the association of blood eosinophilia and myiasis is rare. Often, before the parasitic infestation becomes detectable, eosinophils reach a high level and this can result in an incorrect diagnosis (13). The case report of an adult patient with cutaneous myiasis suffering from multisystem discomfort for nine months who was treated for hypereosinophilic syndrome (14).

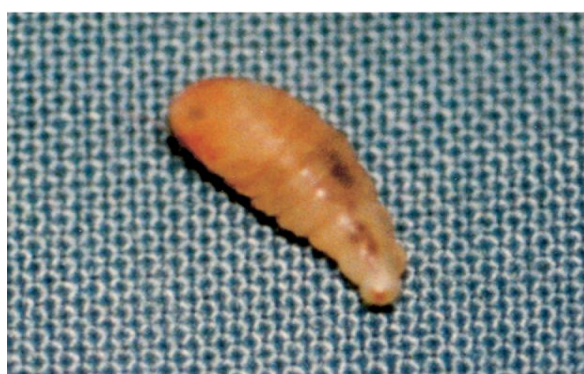
A case of a 54-year-old man who developed recurrent painful migratory subcutaneous nodules and eosinophilic pleural effusion due to myiasis has also been reported (15). Both cases were due to the larvae of *Hypodermalineatum*. To our knowledge, there have not been any reported cases of myiasis due to *W. magnifica* accompanied by eosinophilia and complicated bacterial infections in areas covered by this study. Our report is therefore very significant as it provides baseline information for relevant public health authorities and clinical practitioners on the need to control this problem.

In conclusion, our report presents the first case of myiasis diagnosed by identifying a living fly larva (*Wohlfahrtiamagnifica*) in left scapular muscle of the human body, which could be accompanied by eosinophilia; and bacterial organisms such as *Proteus vulgaris*, *Staphylococcus aureus* and *Staphylococcus*

*epidermidis* were identified within the pus lesion. Clinicians should be more alert to the possibility of myiasis in patients with furuncle-like lesions on their skin.

### References

- [1]. Ahmed A, Egwu, GO, Garba HS, Magaji A, Saliu, MD, Adamu, YA. Bacterial pathogens associated with Lamb Mortality in Sokoto, North Eastern Nigeria. *Vom Journal of Veterinary Science*. 2010;7: 17-20.
- [2]. Arvind KG, Dana N, Pankaj V, Bhavin S, Hemant VG, Milind SP, Yogesh SS. Phylogenetic characterization of bacteria in the gut of house flies (*Muscadomestica L.*). *Journal of FEMS Microbiology Ecology*. 2011;79(3):581-593.
- [3]. Cowan ST. Manual for the identification of medical bacteria 2nd ed. edited by S.T Cowan and K.J Steel Cambridge. Cambridge university press 1993; 75-78.
- [4]. Ciftcioglu N, Altintas K, Haberal M. A case of human orotracheal myiasis caused by *Wohlfahrtiamagnifica*. *Parasitol Res*. 1997;83: 34-36.
- [5]. Das SK, Dasgupta B. Seasonal Occurrence of Blow flies and Flesh flies in Calcutta. *Journal of Oriental Insects*. 2012;16(1):1982.
- [6]. Farkas R, Hall MJ. Prevalence of traumatic myiasis in Hungary: a questionnaire survey of veterinarians. *Vet Rec*. 1998;143: 440-443.
- [7]. Gupta AK. Molecular phylogenetic profiling of gut-associated bacteria in larvae and adult flesh flies. *Journal of Medical Vet Entomology*. 2014; 28(4):345-354.
- [8]. Hall MJ. Trapping the flies that cause myiasis: their responses to host-stimuli. *Ann Trop Med Parasitol*. 1995; 89: 333-357.
- [9]. Iori A, Zechini B, Cordier L, Luongo E, Pontuale G, Persichino SA. A case of myiasis in man due to *Wohlfahrtiamagnifica* (Schiner) recorded near Rome. *Parassitologia*. 1999; 41: 583-585.
- [10]. Kabkaew LS, Sangob S, Tunwadee K, Jeffrey KT, Kom S. *Sarcophaga (Liosarcophaga) dux* (Diptera: Sarcophagidae): A flesh fly species of medical importance. *Biological Research*. 2014;47: 14.
- [11]. Kadam SS, Agrawal BA. Microbiology and Physico-chemical analysis of different sources of drinking water in Dahanu Taluka of Thane District. *European Journal of Experimental Biology*. 2015;5(6):13-22.
- [12]. Kokcam I, Saki CE. A case of cutaneous myiasis caused by *Wohlfahrtiamagnifica*. *J Dermatol*. 2005;32: 459-463.
- [13]. Krzystof S, Anna M, Matuez J, Szymon M. Flesh flies (*Diptera: Sarcophagidae*) colonizing large carcasses in Central Europe. *Journal of Parasitol Res*. 2015;114(6):2341-2348.
- [14]. Krzystof S, Rene R, Thomas P. Third instar larvae of flesh flies (*Diptera: Sarcophagidae*) of forensic importance-critical review of characters and key for European species. *Journal of Parasitol Res*. 2015;114(6):2279-2289.
- [15]. Marcin P, Krzystof S, Andrzej G, Thomas P. A large scale molecular phylogeny of flesh flies (Diptera: sarcophagidae) *Journal of Systemic Entomology*. 2014;39: (4): 783-799.
- [16]. Nandi BC. Studies on the larvae of flesh fly (*Diptera: Sarcophagidae*) *Journal of Oriental Insects*, 2012; 14(3):1980.
- [17]. Starr J, Pruett JH, Yunginger JW, Gleich GJ. Myiasis due to *Hypodermalineatum* infection mimicking the hypereosinophilic syndrome. *Mayo Clin Proc*. 2000;75: 755-759.
- [18]. Tligui H, Bouazzaoui A, Agoumi A. Human auricular myiasis caused by *Wohlfahrtiamagnifica* (Diptera: Sarcophagidae): about three observations in Morocco. *Bull Soc Pathol Exot*. 2007;100: 61-64.
- [19]. Uzun L, Cinar F, Beder LB, Aslan T, Altintas K. Radical mastoidectomy cavity myiasis caused by *Wohlfahrtiamagnifica*. *J Laryngol Otol*. 2004;118: 54-56.
- [20]. Yebenes, M, Munor, C, Sabat, M, Palacio, L, Sanvicente, B, Traveria, FJ, Luelmo, J. Multiple furunculoid myiasis on the scalp of a child. *Dermatology Online Journal*. 2007;13(2): 13.
- [21]. Yuca K, Caksen H, Sakin YF. Aural myiasis in children and literature review. *Tohoku J Exp Med*. 2005;206: 125-130.





**Flesh fly (*Wohlfahrtiamagnifica*)**