

Two cases of Toenail Chaetomycosis from district Jammu (India).

Ruchi Bhou , Geeta Sumbali

Department of Botany, University of Jammu, Jammu (J&K)

ABSTRACT : *Chaetomium* species are found worldwide in the soil and plant debris as saprophytes. They usually colonize cellulose containing plant remains but sometimes may cause opportunistic mycoses, onychomycosis and cutaneous infection in otherwise healthy human beings. In this paper, we report the first two cases of onychomycosis caused by *Chaetomium globosum* in district Jammu (J&K, India). The direct microscopical examination of the nails showed light brown, branched and septate hyphae. The etiological significance of the fungus was confirmed by its repeated isolation at different times, to the exclusion of dermatophytes.

KEYWORDS:- *Chaetomium*, onychomycosis, non-dermatophytic, Toenails, Jammu.

I. INTRODUCTION

Onychomycosis is a chronic fungal infection of the toe or fingernails that gradually leads to destruction of the nail plate. It may be caused by both dermatophytic and non-dermatophytic fungi, but recently the later group is recognized to cause more of onychomycosis among various individuals. The non-dermatophytic fungi are often saprophytic or opportunistic fungi, which were ignored in the past(1). Recently, increase in the number of such cases might be due to improved diagnostic techniques and increased awareness that these fungi are also potential etiologic agents(2). The genus *Chaetomium*, which belongs to Class Ascomycetes, is a dematiaceous mold found worldwide in soil and plant debris as a saprophyte. *Chaetomium* species are rarely involved in human infection, but have been reported to cause subcutaneous phaeohyphomycosis and onychomycosis in healthy subjects(3). Here, we report the first two cases of onychomycosis caused by *Chaetomium globosum* from district Jammu (J&K, India).

II. MATERIALS AND METHODS

For mycological examination, nail clippings and scrapings from suspected individuals were collected with a sterilised scalpel after thorough cleaning with alcohol. These were processed by preparing a wet mount of nail sample in 20% potassium hydroxide (KOH) in dimethyl sulphoxide (DMSO) and then counterstained by chlorazol black E to enhance the visualization of the fungus. All the samples were cultured irrespective of the negative or the positive direct microscopic examination. Samples were cultured on Sabouraud dextrose agar (SDA) medium supplemented with chloramphenicol and incubated at 28-30°C for 21 days. Repeated mycological sampling was done to identify the causal agent correctly. Detection of *Chaetomium globosum* was done by growing them on potato dextrose agar (PDA) medium and by studying their cultural and morphological characters. The identification of the causative fungus was confirmed by clinical findings, repeated fungal isolation and light microscopy.

III. RESULTS

During the period under survey, people residing in different areas of district Jammu (J&K) were scanned for the presence of suspected nail infections. In this communication, we report two cases of onychomycosis caused by *Chaetomium globosum* from district Jammu (J&K). The species was isolated from the diseased toenails of two male individuals. The clinical appearance of the affected nails was distal and distal lateral subungual onychomycosis followed by onycholysis with yellowish, brown to black colouration of the infected nail.

CASE REPORTS

PATHOLOGY OF CASE 1 AND CASE 2

CASE 1

The first case of onychomycosis was detected in a 25-year-old male with complaints of nail dystrophy in the right thumb toenail about two years back. On examination, the thumb nail was dystrophic and brownish to black in color showing hyperkeratosis and onycholysis (Fig.1).

The patient gave a history of working in a field as a farmer and so the thumb nail usually came in contact with the soil.

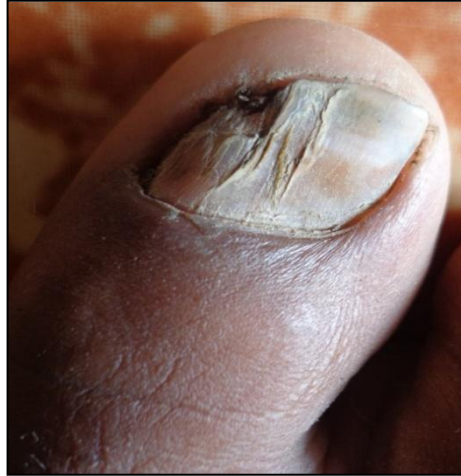

Fig.1. Brownish-Black discoloration with onycholysis on right first toenail (Case1).

CASE 2

The second case of onychomycosis was detected in a 55-year-old male with complaints of nail dystrophy on the left toenails (1st to 3rd) about three years back. On examination, the thumb nail was dystrophic and yellowish-brown in color showing hyperkeratosis and onycholysis (Fig.2).

The patient gave a history of wearing wet socks in shoes. The wet socks retained moisture for a long duration and thus acted as a good source of humidity for the growth of microorganisms.

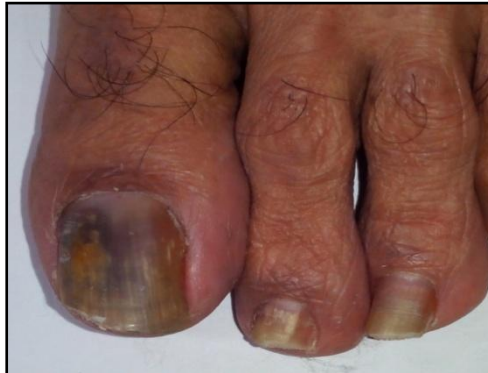

Fig. 2. Brownish-Yellow discoloration with hyperkeratosis on the left toenails (Case2).

MYCOLOGY OF CASE 1 AND CASE 2

Direct microscopic examination of the nail samples in 40% KOH revealed dematiaceous, branched and septate hyphae. The nail samples cultured on Sabouraud dextrose agar medium supplemented with chloramphenicol formed white colonies after 2 weeks, which matured into grey to black colonies (Fig.3).

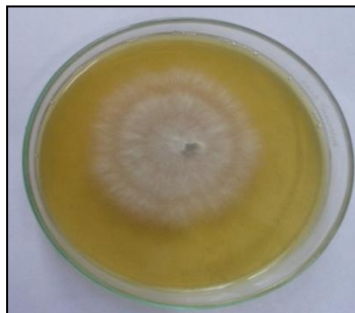


Fig. 3. A rapid growing, grey to brown colony with aerial mycelium on Sabouraud dextrose agar plate after incubation at 25°C for 1 week.

Lactophenol cotton blue mount showed septate hyphae, perithecia, asci and ascospores. Perithecia scattered or gregarious, broadly ovate or ellipsoidal, measuring 200-280x200-260 μm , olivaceous, thickly and evenly covered with slender, flexuous hairs measuring 2.5-3.5 μm in thickness (Fig. 4 and 5).

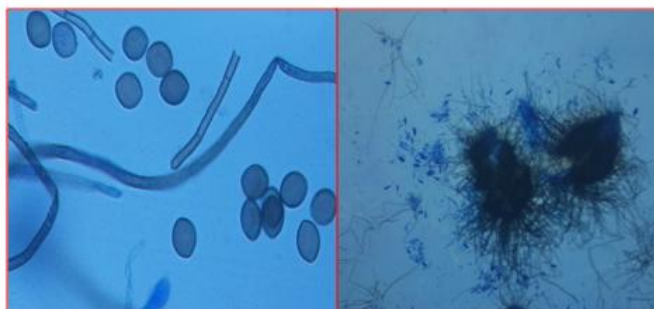


Fig. 4. Brown-colored septate

hyphae with ascospores
(x400)

Fig. 5. Large, dark brown to black, flask shaped perithecia with hair-like filamentous appendages

(x100).

Asci oblong to clavate, evanescent; ascospores dark, broadly ovoid, faintly apiculate at both ends, measuring 7.2-8.8x10.4-11.2 μm (Fig. 6, 7). Based on the above morphological features, the two isolates were identified as *Chaetomium globosum* by using the relevant key (4).

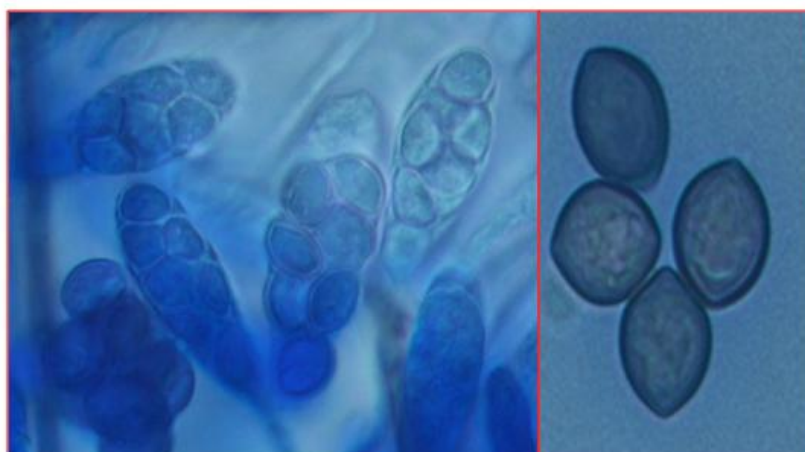


Fig. 6: Asci of *Chaetomium globosum* showing ascospores (x1000).

Fig. 7. Lemon-shaped ascospores (x1000)

IV. DISCUSSION

Onychomycosis constitute frequent fungal infections of the toe or fingernails. The clinical picture is very variable, but in general is characterized by nail architecture alterations, such as, changes in color, thickness, onycholysis and onychodystrophy. Onychomycosis caused by non-dermatophytic molds like *Aspergillus* spp., *Scopulariopsis* spp., *Fusarium* spp., *Acremonium* spp., *Chaetomium* spp., etc. comprise 1.45 to 17.6% of the total cases (5-8). Since the first definition of the genus *Chaetomium* was made by Kuncze, more than 105 species have been listed. They are usually found in association with cellulose-containing substrates, such as, wood, straw and paper (9). Among the 105 species of genus *Chaetomium*, *C. globosum*, *C. atrobrunneum*, *C. strumarium*, *C. perlucidum*, and *C. funiculum* cause infections in the human body. *C. globosum* is most frequently isolated from patients with superficial mycoses such as onychomycosis and cutaneous phaeoophomycosis (15). As non-dermatophytic molds including *C. globosum* are saprophytes, it is not feasible to distinguish the causative agents from contaminants when these molds are isolated from the nail specimens.

To the best of our knowledge, few cases of onychomycosis by *Chaetomium globosum* have been reported from different countries like Spain (9), New York (10), Japan (11), Korea (15), USA (16), Turkey (17) and Czech Republic (18). From India, only two cases have been reported (12, 14). Here, we report the third case of onychomycosis caused by *C. globosum*. Any process that breaks down the integrity of the corneal layer of the nail will facilitate easy penetration by any fungi, including the species that are considered less pathogenic (i.e., *Chaetomium* spp.) and also the occupation of the individual plays a very significant role (19). As shown in table 1, among the two cases of onychomycosis, the first patient gave a history of working as a farmer. Therefore, his feet were in constant contact with soil, which may have lead to colonization of *Chaetomium* in the first toenail. The second patient gave a history of wearing wet socks in shoes, which retained moisture for long duration, thus providing good humidity for the growth and colonization of *Chaetomium globosum* in the nails.

Direct microscopy mount plays a significant part in diagnosing nail fungal infections but the clinical presentation of onychomycosis caused by these filamentous fungi is often unspecific and indistinguishable from

those caused by dermatophytes. Therefore, it should be checked if the characteristic hyphae or spores are present in KOH preparation, if identical colonies are obtained from specimens, and if the same causative mold is identified from repeated cultures (13). In our two cases, fungal elements were found by microscopy, and the same fungal species were isolated from the repetitive cultures of toenail specimens confirming the identification of *C. globosum*. Thus, fungal culture becomes the only definitive test that can be used to identify the species of the infecting organism. Often they are considered as insignificant nail contaminants rather than as etiological agents, invading nails previously damaged by trauma or disease, although in some cases they actually act as primary pathogens, as has been seen for species of the genus *Chaetomium*. Since *C. globosum* was frequently isolated from the onychomycosis patients, one should not consider this as a contaminant but regard it as a causative agent requiring further mycological studies.

Table 1. Clinical and epidemiological characteristics of the two cases infected by *Chaetomium globosum*.

Case	Sex	Age	Occupation	Infection sites	Clinical Signs	Evolution Period	Organisms isolated
Case1	Male	25	Farmer	Toenail	Distal lateral subungual onychomycosis	2 years	<i>C. globosum</i>
Case2	Male	55	Govt. employee	Toenail	Distal subungual onychomycosis	3 years	<i>C. globosum</i>

V. CONCLUSION

Few cases of onychomycosis caused by *Chaetomium globosum* have been reported worldwide. From India, only two cases have been reported (Chandigarh and Jabalpur). Our report is the first one from J&K state. Therefore, their presence must be interpreted with care as the importance of correct etiological identification has to be emphasized for their correct treatment with the currently available antifungals.

VI. ACKNOWLEDGEMENT

The authors are grateful to University Grants Commission (UGC), New Delhi for funding this major research project. The first author also acknowledges financial support in the form of UGC-JRF and SRF.

REFERENCES

- [1] Verma S, Heffernan MP. Superficial fungal infection: dermatophytosis, onychomycosis, tinea nigra, piedra. In: Wolff K, Goldsmith LA, Katz SI, Gilchrist BA, Paller AS, Leffell DJ, editors. Fitzpatrick's dermatology in general medicine. 7th ed. New York: McGraw-Hill; 2008. pp. 1807–1821.
- [2] Gupta AK, Ryder JE, Baran R, Summerbell RC. Non-dermatophyte Onychomycosis. *Dermatol Clin*. 2003;21:257–268.
- [3] Falcón CS, Falcón Ma del MS, Ceballos JD, Florencio VD, Erchiga VC, Ortega SS. Onychomycosis by *Chaetomium* spp. *Mycoses*. 2009;52:77–79.
- [4] LM Ames. A monograph of the Chaetomiaceae : Army Research Office, 1961.
- [5] Gianni C, Cerri A, Crosti C. Non-dermatophytic Onychomycosis. An underestimated entity? A study of 51 cases. *Mycoses*. 2000;43:29–33.
- [6] Gianni C, Romano C. Clinical and histological aspects of toenail Onychomycosis caused by *Aspergillus* spp.: 34 cases treated with weekly intermittent terbinafine. *Dermatology*. 2004;209:104–110.
- [7] Tosti A, Piraccini BM, Lorenzi S. Onychomycosis caused by nondermatophytic molds: clinical features and response to treatment of 59 cases. *J Am Acad Dermatol*. 2000;42:217–224.
- [8] Summerbell RC, Kane J, Krajden S. Onychomycosis, tinea pedis and tinea manuum caused by non-dermatophytic filamentous fungi. *Mycoses*. 1989;32:609–619.
- [9] Aspiroz C, Gené J, Rezusta A, Charlez L, Summerbell RC. First Spanish case of onychomycosis caused by *Chaetomium globosum*. *Med Mycol*. 2007;45:279–282.
- [10] Stiller MJ, Rosenthal S, Summerbell RC, Pollack J, Chan A. Onychomycosis of the toenails caused by *Chaetomium globosum*. *J Am Acad Dermatol*. 1992;26:775–776
- [11] Hattori N, Adachi M, Kaneko T, Shimosuma M, Ichinohe M, Iozumi K. Case report. Onychomycosis due to *Chaetomium globosum* successfully treated with itraconazole. *Mycoses*. 2000;43:89–92.
- [12] Latha R, Sasikala R, Muruganandam N, Shiva Prakash MR. Onychomycosis due to Ascomycete *Chaetomium globosum*: a case report. *Indian J Pathol Microbiol*. 2010;53:566–567.
- [13] English MP. Nails and fungi. *Br J Dermatol*. 1976;94:697–701.
- [14] Naidu J, Singh SM, Pouranik M. Onychomycosis caused by *Chaetomium globosum* kunze. *Mycopathologia* 1991;113:31–4
- [15] 15.KM Dong , LH Myung , SK Moo , HY Gyoung ,K Heesoo , CS Jong. Onychomycosis Caused by *Chaetomium globosum*. *Ann Dermatol*. 2013; 25(2): 232–236.
- [16] L Jean ,C Eric. A case report of a mixed *Chaetomiumglobosum/Trichophytonmentagrophytes* onychomycosis *Med Mycol*. 2012; 1(1): 76–78.
- [17] Kuskucu, K. Midilli N. Kiraz .The first Turkish case of onychomycosis caused by *Chaetomium globosum* in an immunocompetent patient. *Aspergillus and Aspergillosis* website: www.aspergillus.org.uk.
- [18] M Karel , S Magdalena, L Pavlina , Z Eva Phaeoohyphomycosis and onychomycosis due to *Chaetomium* spp., including the first report of *Chaetomium brasiliense* infection. *Medical Mycology* . 2011;49: 724–733.
- [19] Vander Straten RM, Balkis MM, Ghannoum AM. The role of non-dermatophyte molds in Onychomycosis: Diagnosis and treatment. *Dermatol Ther* 2002;15:89–98.