

Midarm Lymphadenopathy - A Rare Presentation Of Filariasis In A 20 Year Old Female In Nanded Region

Dr.V.G.Muddamwar¹,Dr.M.S.Rane²
Dr.S.P.Shewale³,Dr.M.A.Sameer⁴ Dr.S.A.Deshpande⁵, Dr.G.Phasge.

¹(Assistant professor, Department of pathology, Dr.ShankarraoChavan G.M.C, Nanded, India)

²(Resident, Department of pathology, Dr.ShankarraoChavan G.M.C, Nanded, India)

³(Resident, Department of pathology, Dr.ShankarraoChavan G.M.C, Nanded, India)

⁴(Associate professor, Department of pathology, Dr.ShankarraoChavan G.M.C, Nanded, India)

⁵(Professor and head, Department of pathology, Dr.ShankarraoChavan G.M.C, Nanded, India)

⁶(Resident, Department of pathology, Dr.ShankarraoChavan G.M.C, Nanded, India)

ABSTRACT : An 20-year-old woman presented with a midarm swelling clinically suspicious as a enlarged lymph node. Fine needle aspiration cytology (FNAC) of the swelling demonstrated filarial embryo i.e. microfilaria. The microfilaria was confirmed to be of species *Wuchereria bancrofti* by Immunochromatographic card test. This case report signifies the importance of FNAC in early diagnosis of lymphatic filariasis which may present as isolated lymphadenopathy and importance of meticulous screening cytological smears.

KEYWORDS: Bancroftian Filariasis, FNAC, Lymph node, Microfilaria, Midarm swelling.

I. INTRODUCTION

A 20-year-old female from Nanded region of Maharashtra presented in our hospital with a right midarm swelling of size 1.5 x 1.5 cm since 1 and half months (fig1). There was gradual increase in size. Patient had low grade intermittent fever. On general examination patient had mild pallor. Systemic examination was unremarkable. There was no cervical, axillary or inguinal lymphadenopathy. Swelling was mild tender. USG of clinical swelling showed dilation of lymphatics and lymph node showing heterogeneous echotexture along basilic vein (Fig2). Fine needle aspiration cytology (FNAC) of the swelling demonstrated moderately cellular smear with plenty of small and large scattered lymphocytes, centrocytes along with inflammatory cells like histiocytes and few polymorphs, sinusoidal fibers. Also seen two microfilariae on hemorrhagic background material (Fig. 3,4). Impression of inflammatory smear (Filariasis) made. Nocturnal peripheral smear showed no microfilariae. Other Investigations were Hb -9 gm%, TLC -4400/cmm, N-54%, L-38%, E- 6% M-2%, Absolute eosinophil count- 264/cmm, Platelet Count-150000/cmm. The blood tested positive for filarial antigen (ICT TEST). Species of *Wuchereria bancrofti* was confirmed. Patient treated with DEC 6mg/kg for 12 days. There was marked reduction in size confirmed by USG. A final diagnosis of bancroftian filariasis made. FNAC is a vigilant diagnostic tool to diagnose infective inflammatory processes in early stages.

II. DESCRIPTION

Filarial worms are nematodes that dwell in subcutaneous tissues and the lymphatics.

Lymphatic filariasis is transmitted by mosquitoes and is caused by closely related nematodes, *Wuchereria bancrofti* and *Brugia* species (*B. malayi* or *B. timori*) which are responsible for 90% and 10% respectively, of the total number of the infections worldwide⁽¹⁾. Lymphatic filariasis is a major public health problem and it is endemic all over India^(2,3). India contributes to about 40% of the total global burden of the disease and 50% of the population are at risk of infection⁽⁴⁾. While having a look at global burden of disease, about 120 million people are currently infected worldwide and in need of treatment including 40 million disabled and incapacitated by the disease⁽⁵⁾. Despite its high incidence, it is infrequent to find microfilaria in FNAC smears and only incidentally detected in various sites such as lymph node, breast lump, bone marrow, bronchial aspirate, pleural and pericardial fluid, ovarian cyst fluid in clinically unsuspected cases of filariasis with absence of microfilaria in the peripheral blood⁽⁶⁾. Microfilaria has been observed as a coincidental finding with other infective, inflammatory conditions. We found a rare case of mid arm lymphadenopathy showing microfilariae on FNAC. Chief filarial species *Wuchereria bancrofti* is ovo-viviparous nematode having life span of 5 to 10 years of adult worm. They are transmitted by the *Culex* mosquito. Females lay eggs with well developed embryos. Embryo is known as microfilaria. When infected mosquito bites human being larva gets deposited near puncture, which penetrates through skin on its own. It reaches the lymphatic channels, settles

down and become sexually mature. Fertilization has product as microfilariae. They measure about 290 μm in length by 6 to 7 μm in breadth. The sheathed microfilaria of *Wuchereria bancrofti* having multiple, coarse, discrete nuclei extending from the head to the tail, except in the small terminal portion of the caudal end. Thus species are identified by seeing the larval form⁽³⁾ *Microfilaria* shows nocturnal periodicity; this is basically a biological adaptation to the nocturnal biting habit of vector mosquitoes. That is why at least three consecutive night blood sample were examined.

III. CLINICAL FEATURES

The most common presentation of the lymphatic filariasis are asymptomatic (or subclinical) microfilaremia, hydrocele, acute adenolymphangitis (ADL) and chronic lymphatic disease. Virtually all persons with microfilaremia have subclinical disease that includes microscopic haematuria and/or proteinuria, dilated and (tortuous) lymphatics which is visualised by imaging. ADL is characterized by high fever, lymphatic inflammation (lymphangitis and lymphadenitis), and transient lymphatic edema. The lymphangitis is retrograde, extending peripherally from the lymph node draining the area where the adult parasite reside⁽⁷⁾. Most commonly it is observed in 10-20 year of age.

IV. DIAGNOSIS

A definitive diagnosis can be made only by detection of the parasites.

4.1 Rapid immunochromatographic test : It is highly sensitive and specific test for diagnosis of active infection. It detects the circulating filarial antigen indicating presence of bancroftian filariasis. No cross reactivity is seen with Brugia malayi.

4.2 Ultrasonography: It shows presence of adult filarial worms, by the '**Filaria Dance Sign**' (FDS) along with diffuse dilatation of the lymphatic vessels in *W. bancrofti* infection.

4.3 FNAC: FNAC study can show microfilariae even in absence of peripheral blood parasitemia. FNAC also shows inflammatory cells like lymphocytes, histiocytes and granulomatous reaction around dead parasite.

4.4 Histopathology: Histopathological studies of lymph nodes can show adult filarial worms and inflammatory reaction

4.5 Polymerase chain reaction (PCR): Detection of filarial DNA by PCR is highly sensitive and species-specific diagnosis but it is laborious and expensive for routine use.

V. TREATMENT

5.1 Diethylcarbamazine: Diethylcarbamazine 6 mg/kg daily for 12 days has both macro and microfilaricidal properties, it is drug of choice for treatment of active lymphatic filariasis. **5.2 Albendazole:** It is recommended 400 mg twice daily for 21 days. It has macrofilaricidal efficacy

5.3 Doxycycline : 4 to 6 weeks course of doxycycline also has significant macrofilaricidal activity. The addition of DEC to 3 week course of doxycycline has recently been shown to be efficacious in lymphatic filariasis⁽⁷⁾.

VI. DISCUSSION

Garg et al⁽⁸⁾ found similar case of isolated mid arm lymphadenopathy in North India region, which showed microfilaria on histopathological examination.

Kadam et al⁽⁹⁾ found similar isolated lymphadenopathy in supraclavicular region which further on FNAC showed positive for microfilaria.

Filaria is less prevalent in females than in males. This observation also reflects a relatively higher exposure of males to mosquito bites and other anatomical and hormonal differences between males and females. Gender specific physiological factors such as hormones have been suspected of affecting parasite establishment in the human host⁽¹⁰⁾.

Thus we found a rare case of isolated mid arm lymphadenopathy in 20 yr female on fine needle aspiration.

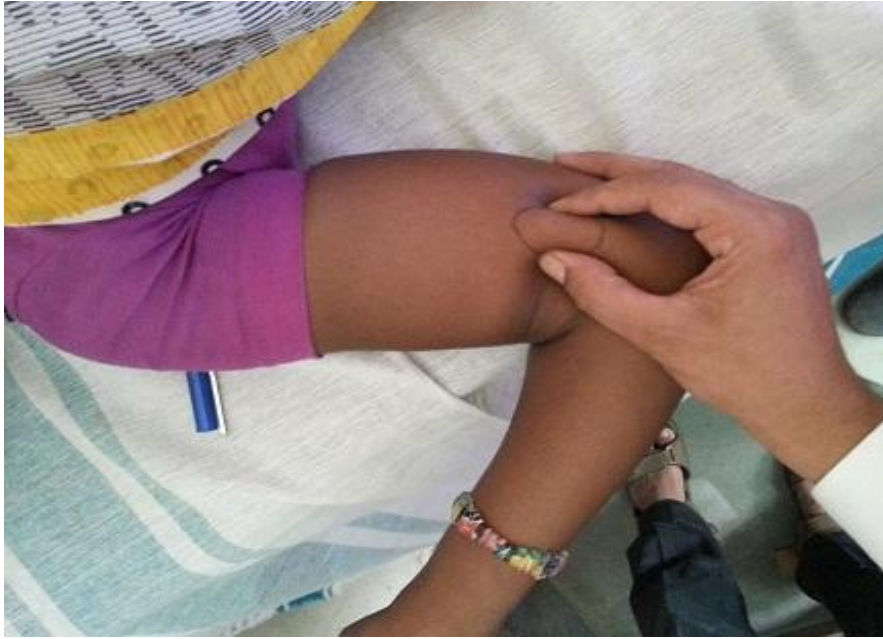

Fig 1:Enlarged lymph node

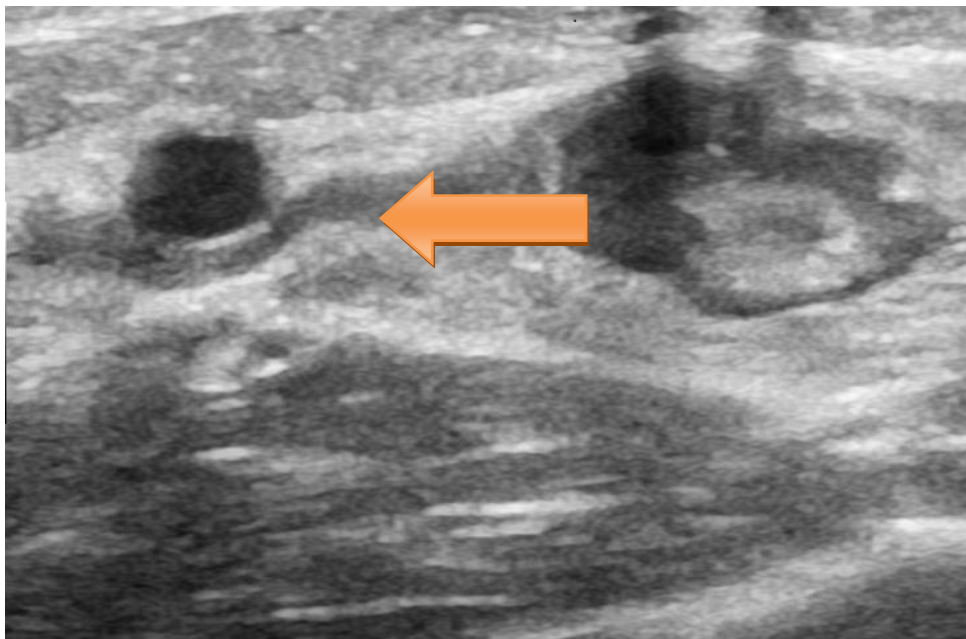


Fig2:dilated lymphatic ductule along with connecting lymph node

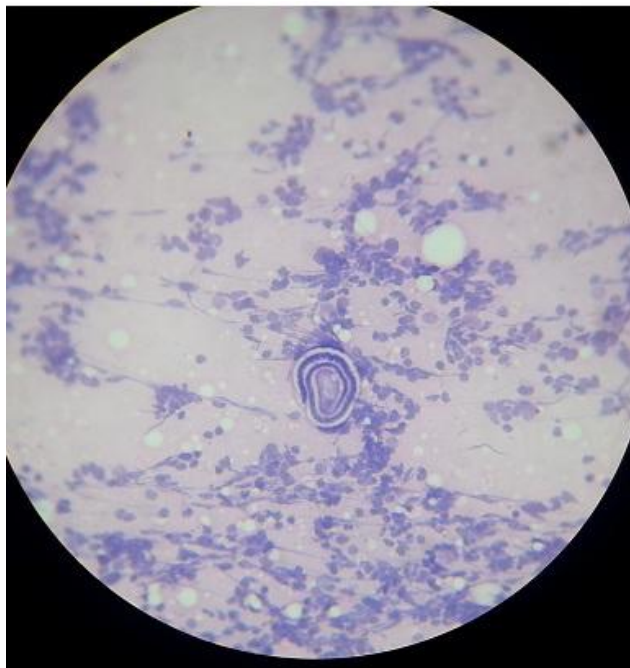

Fig3: First microfilaria H& E 40 X

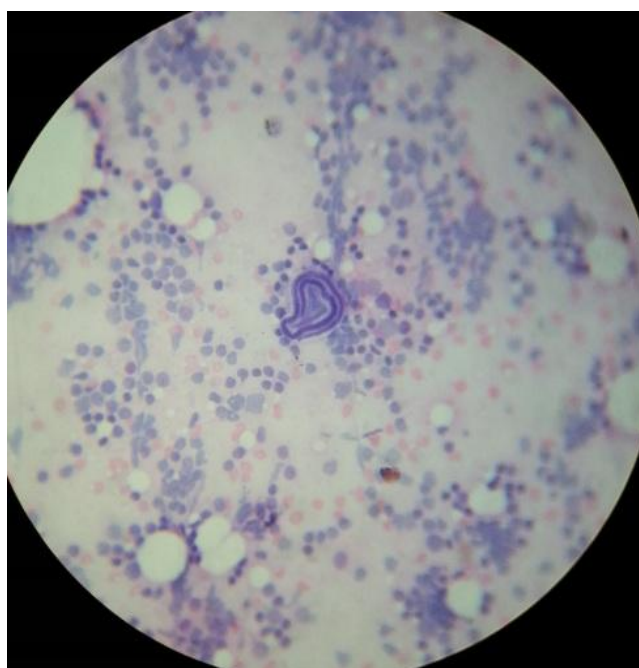

Fig4:Second microfilaria H & E 40X

VII. CONCLUSION

Most of the parasitic infections are curable if diagnosed promptly. FNAC plays significant role in diagnosing filarial infection in asymptomatic, unsuspected cases of filaria, thus avoiding the more severe manifestations of lymphatic filariasis. As absence of microfilaria in the peripheral blood does not exclude filarial infection and tests like ELISA, circulating antigen tests are expensive and labour intensive for routine use. Vigilant screening of cytology smears of clinically suspected swellings might lead to correct diagnosis. Thus FNAC is an excellent cytodagnostic tool to identify infectious inflammatory conditions.

REFERENCES

- [1] Vinaykumar ,Abul K , Abbas , Nelson Fausto.Robins andCotran Pathologic Basis of Disease. Elsevier publisher8th.ed.Chapter 8; page:395.
- [2] Park K. Park's Textbook of Preventive and Social Medicine. 21st ed. Jabalpur, India: BanarasidasBhanot publisher; 2011.Chapter 5; page: 244.
- [3] ChatterjeeD. Parasitology (Protozoology and Helminthology) 12th ed. Calcutta, India: Chatterjee Medical Publishers; 1980; 190–8.
- [4] Michael E, Bundy DA, Grenfell BT (1996) Re-assessing the global prevalence and distribution of lymphatic filariasis. Parasitology 112: 409-428.
- [5] WHO (2009) Weekly Epidemiological Record, No. 11/12, 13th March, 2009.
- [6] Varghese R, Raghuvver CV, Pai MR, Bansal R. Microfilariae in cytologic smears: A report of six cases. ActaCytol 1996; 40 (2): 299-30.
- [7] Longo,Fauci Kasper Hauser, Jameson, Loscalzoharrison's principles of internal medicine The McGraw hill publishing company18th ed. section19 Chaper 218; page :1745-1748
- [8] Pankaj Kumar Gargmid-arm and epitrochlear lymphadenopathy: a clinico-radiological surprise,J Infect DevCtries2011; 5(11):820-824.
- [9] KadamP.N.isolated left supraclavicular lymphadenopathy - a rare presentation of lymphatic filariasis in children.Journal of Evolution of Medical and Dental Sciences/ Volume 2/ Issue 29/ July 22, 2013 page5426-5430
- [10] Brabin L. Sex differentials in susceptibility to lymphatic filariasis and implications for maternal child immunity. Epidemiol Infect 1990; 105:335-53