

Neurohistological Study of the Effect of Ethanolic Leaf Extract of *Sida Acuta* on the Cerebral Astrocytes of Adult Wistar Rats.

¹Mokutima A. Eluwa, ²Chidiebere O. Ubah, ³Amabe O. Akpantah, ⁴Olaitan R. Asuquo, ⁵Theresa B. Ekanem, ⁶Ekaette P. Akpan, ⁷Theresa E. Isamoh.

^{1,2,3,4,5,6,7}Department of Anatomy, Faculty of Basic Medical Sciences, University of Calabar, Calabar, PMB 1115, Cross River State, Nigeria

ABSTRACT: *Sida acuta* commonly called common wire weed, spinyhead sida belongs to the family malvaceae and it serves as one of the medicinal plants used by traditional herbalist for the treatment of various diseases. This study was to assess the effects of ethanolic leaf extract of *Sida acuta* on the cerebral astrocytes in wistar rats. Twenty (20) adult wistar rat were divided into four groups labeled A, B, C and D, each consisting of five rats. Group A served as the control that received distilled water, while the experimental groups B, C, and D received 200mg/kg, 400mg/kg and 600mg/kg of the ethanolic leaf extract of *Sida acuta* respectively for the period of fourteen days. Neurohistological results showed hyperplasia of astrocytes in the group B that received 200mg/kg of the ethanolic leaf extract of *sida acuta*, hypertrophy and hypoplasia of astrocytes in the group C that received 400mg/kg of the extract and hypoplasia of astrocytes in the group D that received 600mg/kg of the extract. Thus, these results suggest that administration of ethanolic leaf extract of *Sida acuta* causes hyperplasia, hypoplasia and hypertrophy of reactive astrocytes in the cerebral cortex of wistar rats and these changes may result in cerebral dysfunction.

KEYWORDS: Ethanolic extract, *Sida acuta*, Cerebral cortex, Astrocytes, Wistar rats

I. INTRODUCTION

Nowadays, the use of complementary/alternative medicine and especially the consumption of botanicals have been increasing rapidly worldwide, mostly because of the supposedly less frequent side effects when compared to modern western medicine [1]. The herb *Sida acuta* is a small shrub, belonging to the Malvaceae family found widely in the tropics [2]. An ethnobotanical investigation in the central region of Burkina Faso has shown that many species are traditionally used to treat various kinds of pain diseases. Among such plants, *S. acuta* Burn f. and *S. cordifolia* L. (Malvaceae) are the most frequently and widely used. These plants are used to treat infectious diseases in children such as malaria, fever, pain, variola, and also have antibacterial, anti-inflammatory, analgesic and hepatoprotective properties [3, 4].

Pharmaceutical and phytochemical literature reports have shown that an extract of *sida acuta* exhibits anti-malarial activity [5]. It is used in alternative system of medicine as bitter tonic, diuretic, in nervous and urinary diseases, disorders of bile, chronic bowel complaints and in the rheumatic affections. It is also used in the treatment of intestinal worms, cures fever and headache [6-9]. The plant is reported to have antifertility activity [10], antibacterial activity [11], anti-inflammatory, hepatoprotective activity [12], traditional healing for snakebites [13] and anti-hepatotoxic actions [14]. In Malacca, the leaves and root are boiled and may be used for poulticing the chest to treat coughs. The pounded leaves are used to promote the healing of wounds and are also used to address influenza, toothaches, chest pains, ulcers, scabies, abscesses, impotence, gonorrhoea and rheumatism [15]. They are limited data on the effect of herbal medicine on the cerebral astrocytes and its effect has not been fully documented. Thus the aim of this research is to find out the effect of ethanolic leaf extract of *Sida acuta* on the cerebral astrocytes.

II. MATERIALS AND METHODS

Twenty (20) female adult wistar rats weighing between 180 –220g used for this study were obtained from the animal house of the Department of Pharmacology, University of Calabar. These animals were kept in the animal house of the Department of Human Anatomy for two weeks to acclimatize. The animals were fed with growers mash obtained from vital feed company, at No. 2 Mount Zion Street, Calabar and had access to drinking water ad libitum. After the acclimation period, they were randomly divided into a control and experimental groups

2.1 Extract Preparation

The leaf of *Sida acuta* was collected from University of Calabar botanical garden and authenticated by the botanist in the botanical garden in the University of Calabar. The leaves were washed in water to remove impurities after which they were dried under a shade. The dried leaves were then blended to powdery form and kept in glass container. The extraction method involved cold ethanolic extraction. The rats were divided into four groups labeled A, B, C and D, each consisting of five rats. The rats in Group A serve as the control group and received distilled water while the rats in Groups B, C and D the experimental animals received 200mg/kg, 400mg/kg, 600mg/kg body weight of *ethanolic* leaf extract of *Sida acuta* respectively for 14 days with an aid of *orogastric* tube.

2.2 Termination of experiment

Twenty four hours after the last administration, the rats were sacrificed using the chloroform inhalation method. The cerebral cortex was extracted and immediately fixed in 5% formaldehyde for histological studies. Routine histological processes was carried out and stained for astrocytes using Hortegas lithium carbonate method for reactive astrocytes.

III RESULTS AND DISCUSSION

The astrocytes were demonstrated using Hortegas lithium carbonate method. The cerebral cortex of the control group A showed the normal distribution of astrocytes stained black (Fig 1). Sections of cerebral cortex from group B animals that received 200mg/kg of the ethanolic leaf extract of *sida acuta* showed hyperplasia of astrocytes (Fig 2). Sections of cerebral cortex from the treatment group C animals that received 400mg/kg of the ethanolic leaf extract of *sida acuta* showed hypertrophy and hypoplasia of the astrocytes. (Fig 3). Sections of cerebral cortex from the treatment group D that received 600mg/kg of ethanolic leaf extract of *sida acuta* showed hypoplasia of astrocytes. (Fig 4). The cerebral cortex is the layer of the brain often referred to as gray matter. The cortex is gray because nerves in this area lack the insulation that makes other parts of the brain appear white and plays a role in memory, attention, excitatory awareness, thought, language and consciousness [16]. Reactive astrocytosis occurs prominently in response to all forms of CNS injury or disease. Studies have shown the roles played by reactive astrocytes in restricting inflammation, protecting neurons and oligodendrocytes, order to limit tissue degeneration and preserve functions after injury to the CNS [17]). In this study, findings revealed hyperplasia of astrocytes in groups B animals that received 200mg/kg of the ethanolic leaf extract and hypoplasia of astrocytes in the experimental groups C and D that received 400mg/kg and 600mg/kg of the ethanolic leaf extract of *sida acuta* when compared with the control.

The result is in line with the work reported by Ekong [18] that larimal an antimalarial, though effective in malarial treatment has the potential to cause cerebellar tissue damage, evidenced by hypertrophy and hyperplasia of reactive astrocytes. A study carried out by Ekanem [19] on the reactive astrocytes in the hippocampus of adult wistar rats after three day administration of combination of antimalarial drugs mefloquine and artequine showed large, numerous, and some few paired astrocytes. The increased population of reactive astrocytes formation is meant to protect neurons by providing nutritionally rich environment for neuronal survival following possible adverse effects produced by these drugs Damages to the central nervous system (CNS) result in a glial reaction, leading eventually to the formation of glial scar. The glial reaction to injury recruits microglia, oligodendrocytes precursors, meningeal cells, astrocytes and stem cells (20).

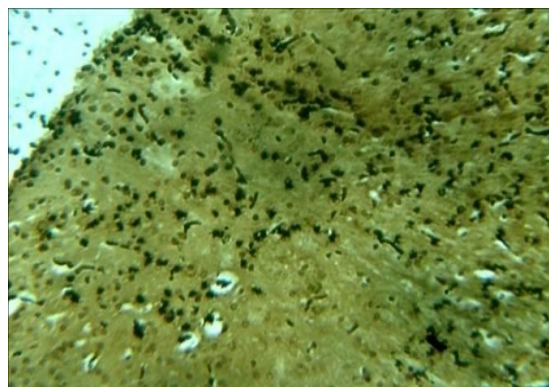


Figure1: Photomicrographs of cerebral cortex of Control showing protoplasmic astrocytes stained astrocytes (Hortegas lithium carbonate stain X 100).

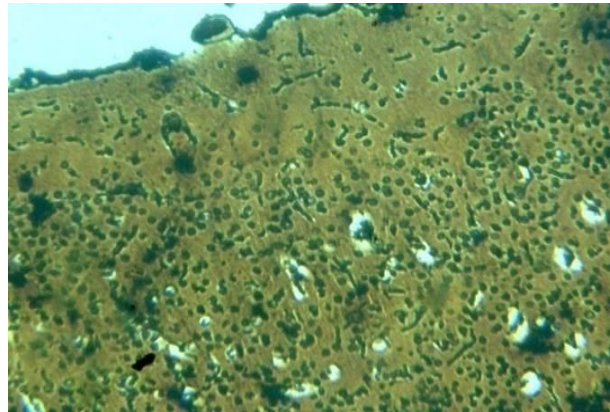


Figure 2: Photomicrographs of cerebral cortex of 200mg/kg of ethanolic leaf extract of *sida acuta* showing hyperplasia (Hortegas lithium carbonate stain X 100)

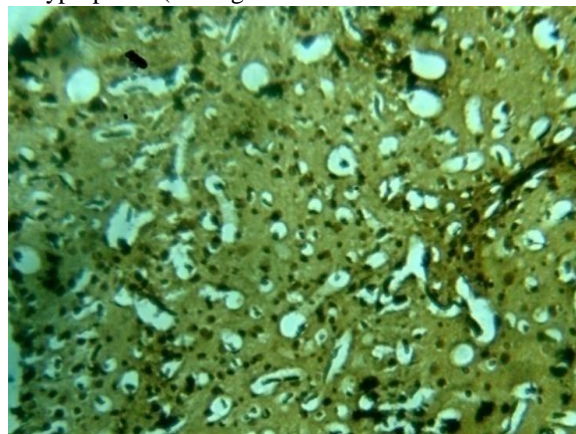


Figure 3: Photomicrographs of cerebral cortex of 400mg/kg) hypoplasia of astrocytes (Hortegas lithium carbonate stain X 100).

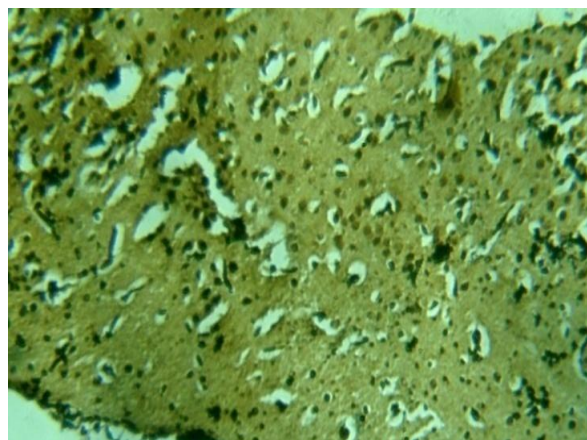


Figure 4: Photomicrographs of cerebral cortex of the extract of *sida acuta* showing hypertrophy and hypoplasia of astrocytes (Hortegas lithium carbonate stain X 100).
600mg/kg of extract of *sida acuta* showing

IV CONCLUSION

This study suggests that ethanolic leaf extract of *sida acuta* has a potential of neuronal damage as seen in the hypoplasia, hyperplasia and hypertrophy of reactive astrocytes in the cerebral cortex to undergo hypertrophy, hyperplasia and hypoplasia and may impair uptake of neurotransmitters and alter neuronal environment, thus altering cerebral cortex functions such as sensory perception.

REFERENCES

- [1]. Hu X, Sato J, Oshida Y, Yu M, Bajotto G, Sato Y. Effect of Gosha-jinki-gan (Chinese herbal medicine): Niu-che-sen-qi- wan on insulin resistance in STZ induced diabetic rats. *Diab Res Clin Pract.* 59, 2003, 103–111. doi: 10.1016/S0168-8227(02)00203-6.
- [2]. Herbal Medicine Research Centre, Institute for Medical Research, Kuala Lumpur. Compendium of Medicinal Plants used in Malaysia. 2, 2002, 341-342.
- [3]. Nacoulma OG. *Medicinal plants and their traditional uses in Burkina Faso. PhD Thesis.* University of Ouagadougou, Biochemistry-microbiology department; 1996.
- [4]. Karou D, Dicko MH, Simpore J, Traoré AS. Antioxidant and antibacterial activities of polyphenols from ethnomedicinal plants of Burkina Faso. *Afr J Biotechnol* (4), 2005, 823-828.
- [5]. Karou D, Dicko MH, Sanon S, Simpore J, Traore A.S. Antimalarial activity of *sida acuta* Burm F, (malvaceae) and *pterocarpus erinocarpus* Poir (fabaceae). *J Ethnopharmacol.* 89, 2003, 91-294.
- [6]. Krishnamurthi A and Chada YR (eds). Wealth of India. Publication and Information Directorate, CSIR, New Delhi. 9th 1972 . p. 322-26.
- [7]. Nadkarni KM. Indian Materia Medica. Popular Prakashan, Mumbai. 1, 1993, 1134-35.
- [8]. Kiritikar KR and Basu BD. Indian Medicinal Plants. International Book distributors, Dehradun, India. 1995. p. 308-9.
- [9]. Ahmad Moghos U, Hussain SK, Ahmed M, Ooman SM and Subbaro R. Cyclopropanoid FA in seed oils *Sida acuta* and *Sida rhombifolia* (Malvaceae). *J Am. Oil Chem. Soc.* 53, 1976, 698-99.
- [10]. Kholute SD, Munshi SR, Naik SD and Jathar VS. Antifertility activity of indigenous plants *Sida carpinifolia* Linn and *Podocarpus brevifolius* Stap in female rats. *Indian J Exp Bio.* 16, 1978, 696-98.
- [11]. Sushil kumar, Bagchi GD, Darokar MP and Kumar S. Antibacterial activity observed in the seeds of some coprophilous plants. *Int J Pharmacology.* 35, 1997, 179-184.
- [12]. Kurma Rao and Mishra SH. Anti-inflammatory activity and hepatoprotective activities of *Sida acuta*. *Indian Drugs.* 35, 1998, 92-97.
- [13]. Otero R, Nunez V, Jimenez SL, Fonnegra R, Osorio RG, Garcia ME and Diaz A. Snakebites and the ethnobotany in the Northwest region of Colombia. Part II: neutralization of lethal and enzymatic effects of *Bothrops Otrox* venom. *J Ethnopharmacol.* 71, 2000, 501-11.
- [14]. Yang LL, Yen KY, Yoshinobu Kiso and Hiroshi Hikino. Antihepatotoxic actions of Formosan plant drugs. *J Ethnopharmacol.* 9, 1987, 103-110.
- [15]. Nature Club Wildlife India: http://www.blackbuck.org.in/wildplants/wild_ian2000.htm accessed on May 2007.
- [16]. Regina Bailey (2008). Cerebral cortex. About.com: Biology. <http://biology.about.com/od/anatomy/a/aa032505a.htm>.
- [17]. Sofroniew MV. Reactive astrocytes in neural repair and protection. *Neuroscientist.* 11(5), 2005, 400 -7.
- [18]. Moses. B. Ekong, Anozeng O. Igiri, Otu. E. Mesembe, Elizabeth salami, Mokutima A Eluwa, Amabe O, Akpantah, Theresa. B. Ekanem . Effect of Larimal on Nissl substances and reactive astrocytes in the cerebellum and adult wistar rats. *J Anat sci.* 29(1), 2009, 9-12.
- [19]. Ekanem, T.B., E salami, M. B. Ekong, M. A. Eluwa, A. O. Akpantah. Combination Therapy Antimalarial drugs Mefloquine and Artequin induce Reactive Astrocytes formation In the Hippocampus of rats. *The Internet Journal of Health.* Volume 9 number 2. 2009.
- [20]. Fawcett, JW, Richard A.A. "The glial scar and central nervous system repair" *Brain Research Bulletin.* 49(6), 1999, 377-91.