

Ultrasonography Technique and Its Role in Diagnosis of Acute Appendicitis

Dr. Amit Kumar Yadav
Junior Resident

Dr. Shephali Pawar,
Professor and Head of Department,
Department of Radiodiagnosis
B.J. Government Medical College and Sassoon General Hospital
Pune, Maharashtra.

ABSTRACT

Acute appendicitis is the one of the most common surgical abdominal emergency in India. Ultrasonography plays an important role in early diagnosis and treatment and in preventing undue complications. This study was performed to evaluate the sensitivity, specificity, positive and negative predictive values of ultrasonography for diagnosis of acute appendicitis. A total of 200 cases from 2 years to 67 years of age admitted in the hospital with suspicion of acute appendicitis subjected to ultrasonography, few other tests, followed up and managed. Among the 200 cases studied, 150 were of acute appendicitis proved surgically. Male to Female ratio was 1.5:1 for acute appendicitis. Most of the patients were from 20 to 30 years of age. Location of the appendix was most commonly retrocaecal (in 75.9% cases). Most commonly detected sonographic sign was target sign. Sensitivity and specificity for ultrasonography was 96.1% and 95.65%. 6 cases were false negative and 2 cases were false positive. Positive predictive value was 98.66% and negative predictive value was 88%. Ultrasonography is a real time imaging technique which does not have hazards of ionization. It is a time saving, cost effective investigation. It can be used at bedside for critical patients. It is also safe to use in pregnant patient.

KEYWORDS: Ultrasonography, Diagnosis, Appendicitis

I. INTRODUCTION

Acute appendicitis is the one of the most common surgical abdominal emergency in India. Young adults are more susceptible for acute appendicitis. Delay in diagnosis or treatment can have detrimental outcomes. Since surgery is the main treatment for this disease, early diagnosis plays a very important role in early diagnosis, treatment and prevention of undue complications.

Acute appendicitis is relatively less common in infants, and becomes more common in late childhood and early adult life with a peak incidence in teens and early 20's. In about 25-30% of patients the signs, symptoms and laboratory findings of acute appendicitis can be atypical which leads to delay in diagnosis and surgical intervention and consequent increase in incidence of complications.

Several other diseases can have clinical and lab findings similar to that of appendicitis leading to negative appendectomy rate of 20-25%, this rate is particularly high (35-36%) for female patients during their reproductive years because of various gynecologic diseases.

Puylaert et al advocates use of graded compression ultrasound using high frequency linear transducers in supine position for diagnosis of acute appendicitis.

Ultrasound can diagnose acute appendicitis accurately and can also diagnose a number of conditions that mimic appendicitis clinically. Sonographic exclusion of appendicitis has two major benefits-It prevents unnecessary appendectomy and appropriate treatment instituted. Ultrasound is highly recommended in children and in young women (due to high incidence of tubal disease), and in patients who are pregnant.

HISTORICAL ASPECTS

First successful use of ultrasound for medical diagnosis was done by Karl Dussik & his brothers Fredrick. During 1947-48 they introduced hyper phonography. In 1949 George Ludwig et al, United States of America used sonography for detection of gall stones and foreign bodies. In 1962 Douglas Howry & Coworkers completed the construction of compound contact scanner.

Pioneering researchers began the application of ultrasound for diagnostics in 1950s. Christian Johann Doppler described 'doppler' the phenomenon. It refers to the change in frequency (or wave length) of sound with the relative motion of the source and observer. Commercial development of Use of Ultrasound equipment for

commercial purposes began in the early 1960's. During past 45 years Ultrasonography came a long way. Not only have newer clinical uses for ultrasound been developed, significant advances in equipment have improved image quality and in turn opened up new vistas in medical diagnosis.

PHYSICAL PRINCIPLES OF ULTRASOUND

Ultrasound is a high frequency mechanical vibration produced by a transducer made of piezoelectric material which has the property of changing thickness when a voltage is applied across it. Lead Zirconate Titanate (PZT) is most widely used material. The vital ingredients of a sonic imaging system are

1. A transducer,
2. A ultrasonic beam, and
3. Diagnostic frequencies of ultrasound ranges from 2.5 MHz and 15MHz.

Ultrasound beam are longitudinal waves that transmit energy. These travel between central body tissues at a speed of 1540m/s. On passage o through the body, the beam is attenuated by a combination of refraction, diffusion, reflection, and some absorption. Reflection of the waves occurs mainly at the tissue interface. The quantity of reflection depends on acoustic impedance of the two surfaces and the angle of incidence of the ultrasound wave.

Ultrasound image display

It is the electronic representation of the data generated from returning echoes. It is displayed on a monitor or cathode ray tube.

1. **A - Mode (Amplitude Modulation) Trace:** It is a single line of information in space that represents the time, or distance, it takes for the beam to strike the interface and the return of the signal back to transducer.
2. **B - Mode (Brightness Modulation) Trace:** When the trace of the A - Mode is rotated by 90 degrees, the spikes are seen as dots.
3. **Gray - Scale Imaging:** It uses scan conversion memory tube (also called scan converter). It stores the information received from transducer and then this stored information is used for generating a signal which produces visible image on Television monitor.
4. **M - Mode (Time - Motion Mode) Trace:** The M - Mode trace uses the concept of A and B - Mode across the screen over some time. It is widely used for depiction of movement and is especially useful in fetal heart movement and cardiac studies.

SONOGRAPHY OF GASTROINTESTINAL TRACT

Gastrointestinal ultrasonography can be challenging, as gas within the gut lumen reduces visibility of underlying bowel. Intraluminal fluid may sometimes be confused with cystic masses. However normal gut has a reproducible gut signature and a variety of gut pathologies creates specific sonographic abnormalities. In acute conditions like such as acute appendicitis and acute diverticulitis, ultrasonography may play a major primary investigative role.

Ultrasonography of normal Appendix

The normal appendix appears as a small, easily compressible, concentrically layered, mobile, blind ending, and sausage-like structure. The diameter is usually less than 7 mm, but can be greater incidentally. The normal appendix is mobile, usually with a collapsed lumen, but also may contain air or some fecal material, and rarely a little fluid. Colour Doppler reveals scarce or no vascular signal and there is no hyperechoic, non-compressible inflamed fat around the appendix.

ACUTE APPENDICITIS- A PATHOLOGICAL PERSPECTIVE

Luminal obstruction causes distension of the appendix which leads to accumulation of mucinous secretions. This is followed by vascular compromise of the wall and secondary bacterial invasion by enteric organisms.

Appendicitis is classified various stages. In the beginning acute reaction is marked by neutrophilic infiltration throughout the thickness of the wall and the lumen is filled with pus. There is congestion of the subserosal vessels which leads to fibrinous exudate that covers the serosa. All these events lead to acute inflammation of the appendix.

After this hyperacute stage, there is more marked neutrophilic infiltration that causes foci of suppurative necrosis in the wall and the mucosa. It causes sloughing necrosis. This purulent exudate further extends to the enveloping omentum leading to acute suppurative appendicitis.

Acute suppurative appendicitis if left untreated develops gross edema and compromised perfusion to the appendix. Greenish black hemorrhagic ulceration of the mucosa and green - black foci of necrosis in serosa develop leading to acute gangrenous appendicitis.

Acute Gangrenous appendicitis then ruptures and may form periappendiceal abscess or cause generalized peritonitis.

CLINICAL ASPECTS OF APPENDICITIS

Even though etiology of acute appendicitis is less known. Various factors like diet (low residue diet), social status (high middle class and upper class), genetics, appendicoliths, foreign body, round worm or thread worm or a stricture and indiscriminate use of purgatives are all incriminated. Although no age is exempt, it is uncommon before the age of 2 years. It becomes increasingly common during late childhood and adolescence and the maximum incidence is noticed between 15 and 30 years.

Clinically two types of acute appendicitis are seen:

- a. Non-obstructive type appendicitis
- b. Obstructive type appendicitis.

Non-obstructive type of appendicitis usually progress in a slow pace, whereas obstructive appendicitis has a very fast progression. Complications like gangrene and perforation are associated with obstructive type of appendicitis. A careful history has to be taken. Pain centered around the umbilicus in the initial phase and later shifting to the right iliac fossa region is characteristic of acute appendicitis. The initial pain is often visceral and is perceived in the midline independent of the appendiceal position, since appendix developmentally is a medial organ. Pain which occurs later is due to irritation of parietal peritoneum which is abutting the appendix.

The nature of pain is dull aching in non obstructive appendicitis, and is colicky in obstructive type. Pain is then followed by severe nausea and vomiting. High grade fever may also be seen. Hyperaesthesia along the Sherrin's triangle, tenderness at the Mc Burney's point, muscle guarding and rebound tenderness are various signs associated with acute appendicitis. Another sign is Rovsing sign. After a few days in untreated patients, a mass like lump develops at the appendiceal site also called the appendicular lump.

There may be temporary improvement in pain if appendicular perforation occurs. However, other signs like severe vomiting and generalised pain are more prominent.

Acute Appendicitis in pregnant women

Acute appendicitis is a common cause of RIF pain in pregnant women. USG is the initial imaging investigation of choice in the evaluation of acute abdominal pain in obstetric patients, because of the safety, inexpensive nature. CT is not recommended because of radiation hazards.

ULTRASONOGRAPHIC FINDINGS OF ACUTE APPENDICITIS

The typical findings of acute appendicitis on transverse ultrasonography are a dilated appendix, the target sign with a hypoechoic center, an inner hyperechoic rim and an external hypoechoic rim. In sagittal plane images, the inflamed appendix is a blind-ending, non-compressible tube like structure. On color Doppler there is increased vascularity mainly in the mucosal layer of the appendix.

ACUTE APPENDICITIS-COLOUR DOPPLER FINDINGS

A normal appendix usually does not have demonstrable blood flow. However if blood flow is seen, a high resistance arterial flow and venous flow with respiratory variations is seen. In case of appendicitis, the vessels in the mesoappendix are engorged and blood flow in them can be easily demonstrated. There may be low resistance arterial waveform and venous flow could be pulsatile.

Gangrenous appendicitis may show absent color flow on Doppler. Use of color Doppler along with grey scale USG increases the sensitivity of USG for diagnosis of acute appendicitis.

In cases of appendiceal perforation, localised hyperemia in the region of the appendix is seen with an appendicular collection.

OBJECTIVES- The aim of the study was to determine the following

1. The ultrasonographic findings in patients of acute right iliac fossa discomfort.
2. The safety and ease of ultrasonography for diagnosing acute appendicitis, in patients with right iliac quadrant pain.

MATERIALS AND METHODS

The study has been conducted in the Department of Radio Diagnosis, B.J. Government Medical College and Sassoon General Hospital, Pune. It included all the cases referred for Ultrasonography with a clinical diagnosis of acute appendicitis for a period of 18 months. Examination of the patients was done using PHILIPS HD11XE ultrasound machine using 7.5MHz and 3.5 MHz high resolution transducers. Examination of the right iliac quadrant for appendix was done using graded compression technique.

Inclusion Criteria

1. All individuals referred for Ultrasonography with clinical diagnosis of acute appendicitis irrespective of age
2. Patients with past history of recurrent appendicitis who are presenting with acute symptoms, and
3. Cases of acute appendicitis in women who are pregnant.

Exclusion Criteria-

1. Cases of past history of recurrent appendicitis which do not have acute symptoms at present,
2. Patients unfit for surgery due to various ailments.
3. Patients not willing for admission for further management.

Ultrasound of the abdomen was performed in the following technique-

A general examination of the patients' abdomen was performed with lower frequency 3.5 MHz curvi-linear probe followed by examination by higher frequency 7.5MHz linear probe. Ultrasound scan was performed with patient in supine position with application of gradual compression. This compression causes displacement of the shadowing gas contents in caecum and ascending colon allowing visualization of the retro caecal area. Distance between transducer and abdominal contents is also reduced using this technique. Ultrasound scan was done starting from tip of the cecum in transverse plane gradually moving cephalad towards the transverse colon on right side. Scan is further done along the longitudinal plane for confirmation.

The dilated and inflamed appendix is localised by its position just inferomedial to cecum and anterolateral to the iliac vessels on right. If appendix could not be visualised, the point of maximum tenderness is scanned preferentially. After visualization of appendix, the diameter, muscle wall thickness was measured, appendicolith, and collection of fluid in the right iliac fossa were noted.

Laboratory Investigations

Routine laboratory investigations that were done:

1. Hemoglobin, Total and differential white cell counts, ESR
2. RBS
3. Urine analysis
4. Frontal Chest X-Ray
5. USG.

The patients were further followed up and post operative findings were used to determine the accuracy of the Ultrasonography.

Criteria for evaluation:

An inflamed appendix or identification of periappendiceal abscess on ultrasonography was considered positive for the diagnosis of appendicitis. An appendix of diameter less than 7 mm or non-visualization was recorded as a negative result.

II. RESULTS

Table – I Spectrum of diseases which may mimic acute appendicitis in the study.

Disease	Male	Female	Total
Acute Appendicitis	90	60	150
Appendicular Mass	6	2	8
Right Acute Pyelonephritis	-	2	2
Right Ureteric Calculus	6	-	6
Pelvic Inflammatory Disease	-	8	8
Twisted Ovarian Cyst	-	2	2
Ileitis	2	-	2
IleoCaecal Tuberculosis	2	2	4
Carcinoma Caecum	4	-	4
No Abnormality Detected	10	4	14
Total	120	80	200

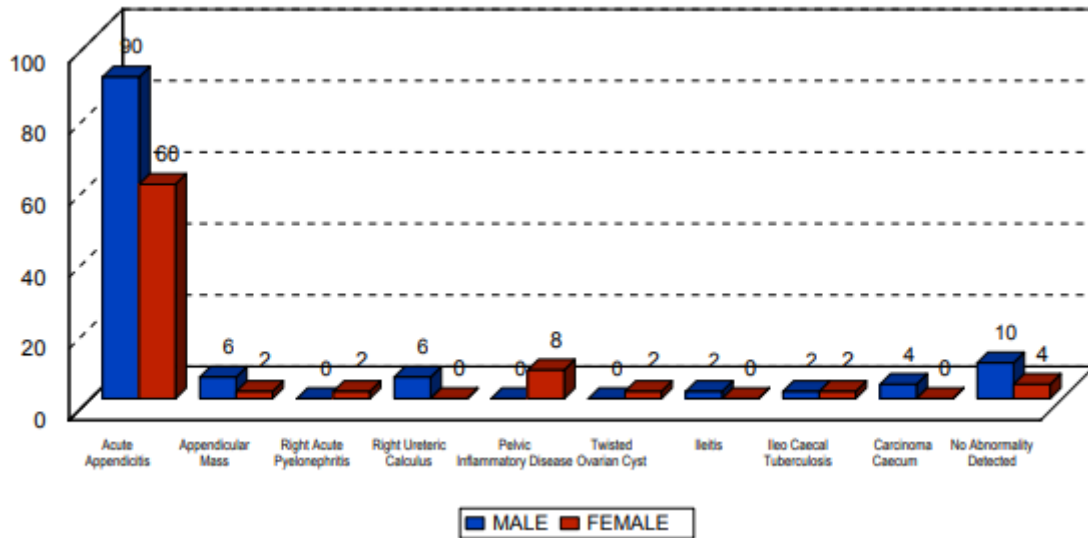


Fig. 1 - Shows the spectrum of diseases which may mimic acute appendicitis in the study.

Table-II: Age incidence of Acute Appendicitis and Appendicular Mass

Age(years)	No.ofPatients	Percentage
0-10	24	15.18
11-20	66	41.77
21-30	34	21.51
31-40	10	6.32
41-50	14	8.86
51-60	6	3.78
61-70	4	2.53
Total	158	100

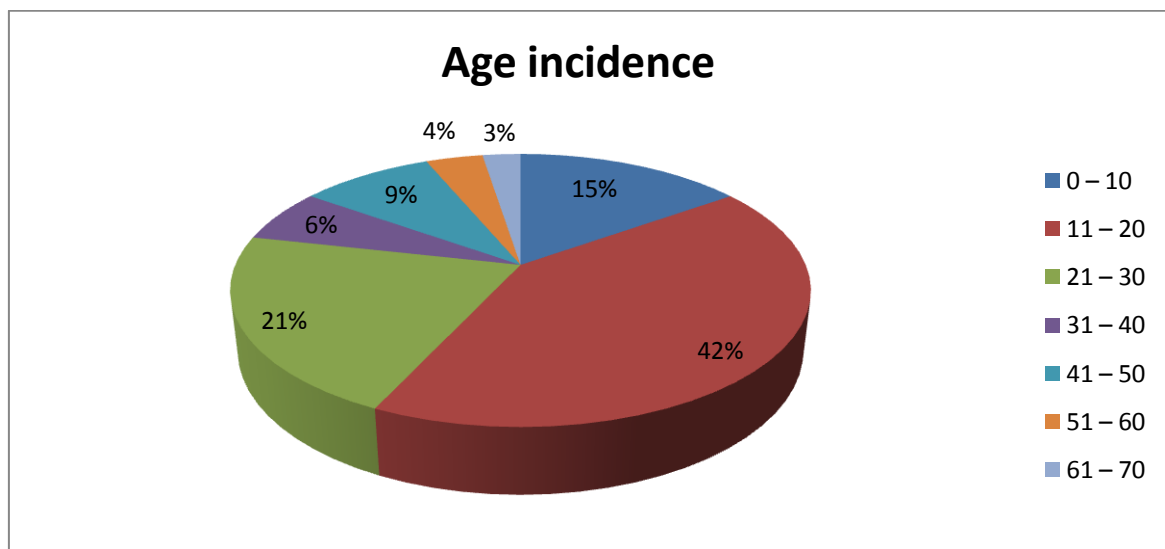


Fig-2: Age incidence spectrum of acute appendicitis

Patients in the age group 11-20 and 21-30 years showed highest incidence of acute appendicitis.

Table–III:Sonographicfindings

Finding	No.ofCases
TargetSign	152
ProbeTenderness	144
FreeFluid	54
Appendicolith	20

Table–IV:CalculationofSensitivityandSpecificity-

SonographicDiagnosis	PatientswithDisease	PatientswithoutDisease
Positive	148(a)	2(b)
Negative	6(c)	44(d)
Totalnumberofcases	-	200
Sonographicallypositiveforappendicitis	-	150
Sonographicallynegative	-	50
FalsePositive	-	2
FalseNegative	-	6

Sensitivity= $(a/a+c) \times 100 = (148/148+6) \times 100 = 96.1 \%$

Specificity= $(d/b+d) \times 100 = (44/44+2) \times 100 = 95.65 \%$

Positive predictive value= $(a/a+b) \times 100 = (148/148+2) \times 100= 98.66 \%$

Negative predictive value= $(d/c+d) \times 100 = (44/44+6) \times 100 = 88 \%$

Table–V:Positionofthe Appendix

AppendixPosition	No.ofCases	Percentage(%)
RetroCaecal	120	75.9
Pelvic	28	17.7
SubCaecal	4	2.5
PreIleal	2	1.26
PostIleal	2	1.26
SubHeaptic	2	1.26
TOTAL	158	100

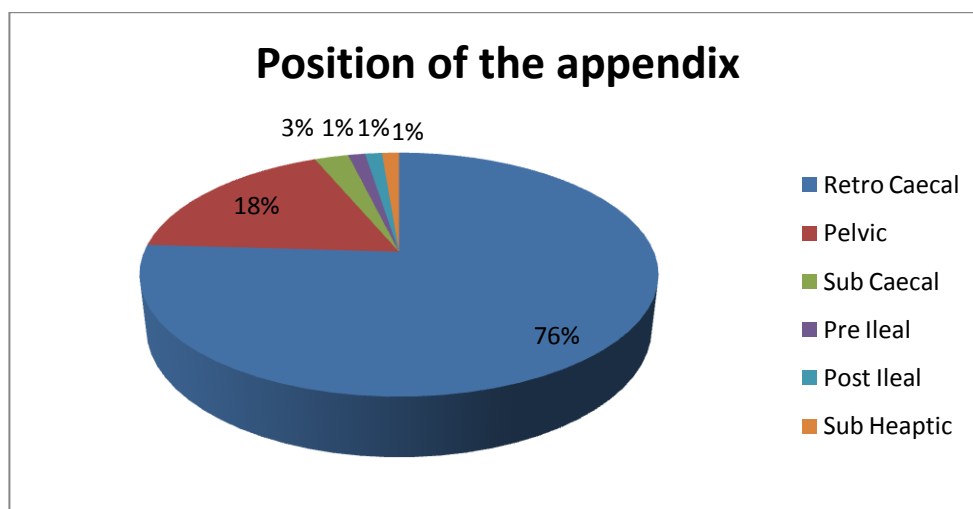


Fig-3:Positionofthe Appendix

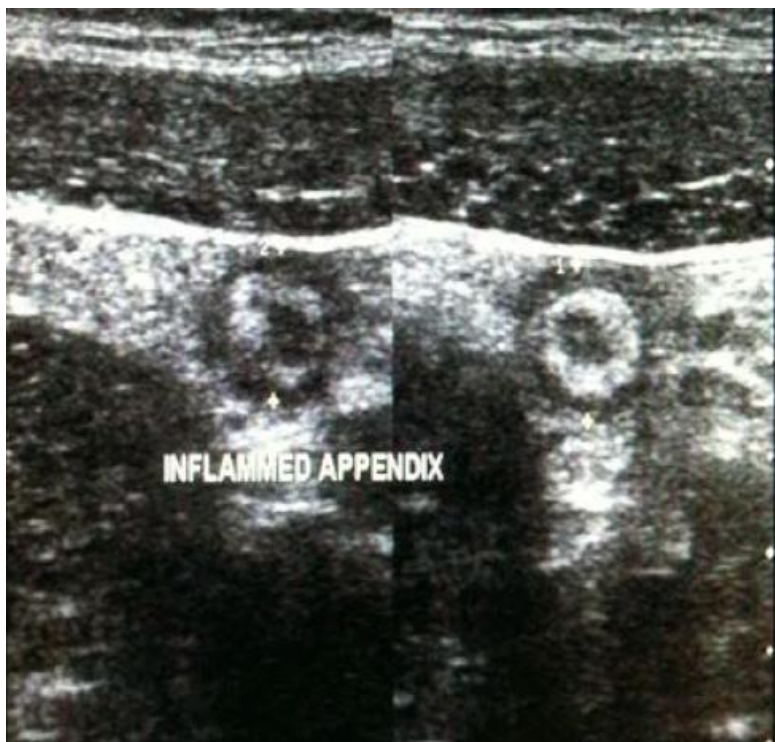

Fig- 4: Target sign of acute appendicitis on USG

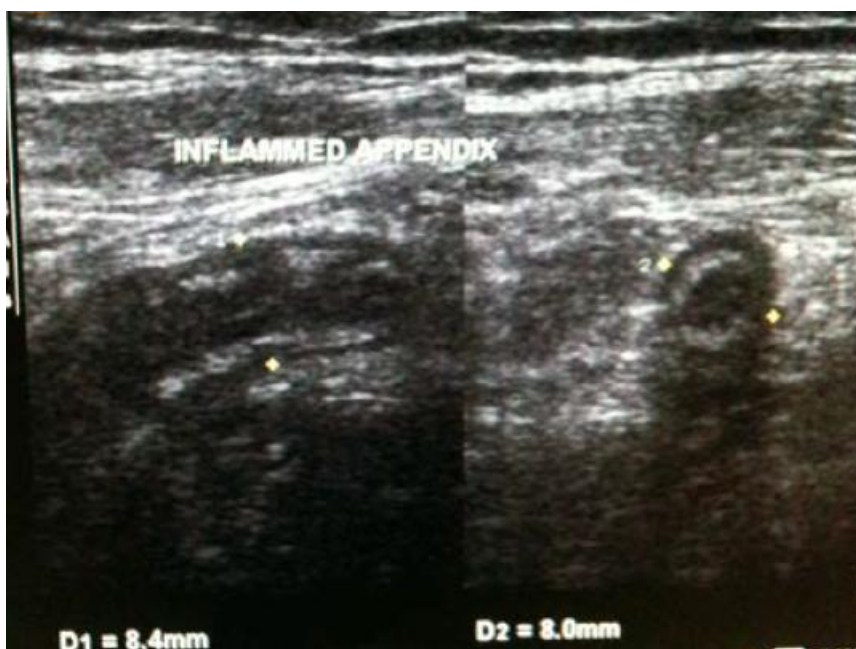

Fig -5: Dilated appendix with mucosal irregularity and irregular wall thickening.

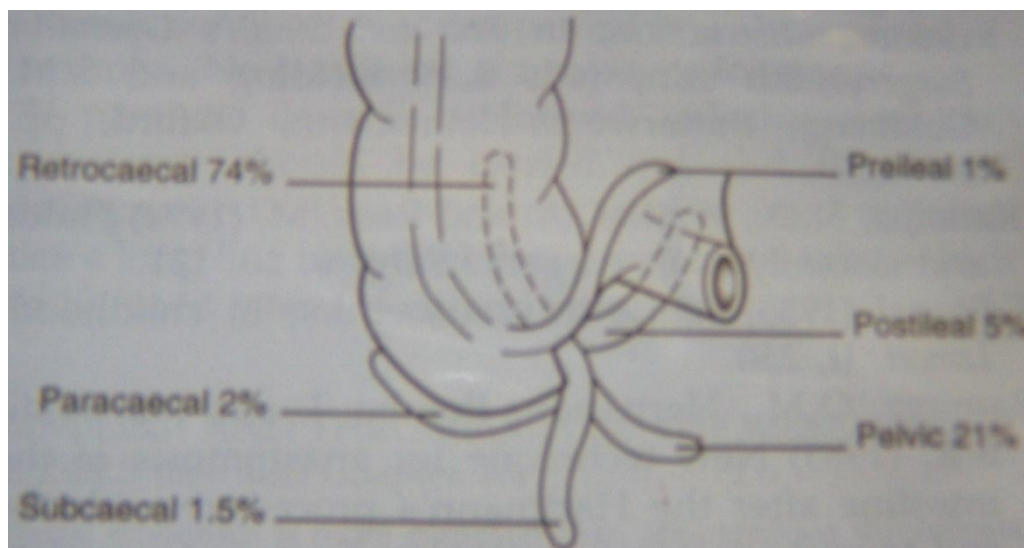


Fig-6: Diagram showing different positions of the appendix

III. RESULTS AND DISCUSSION

Ultrasonography is the most commonly used technique for diagnosis of acute appendicitis. The development of graded compression technique of USG by Puylaert JBCM in 1986 has increased its diagnostic value for acute appendicitis. The present study comprises of 200 selected patients admitted for treatment with clinical diagnosis of acute appendicitis. A careful and detailed history and clinical examination was done after which, USG examination of entire abdomen and of the right iliac fossa region was done using graded compression technique as explained by Puylaert, employing high resolution, high frequency probes (linear array 7.5MHz and curvilinear array 3.5 MHz). The following were the findings-

1. About 63% cases of acute appendicitis are seen in the age group 20-30 years.
2. Male to female ratio was 1.5:1, so males were more commonly affected than females
3. Commonest ultrasound feature in the study was target sign.
4. Commonest position of appendix in the study was retrocaecal appendix.
5. False negatives in the study were 6, false positives were 2.
6. Sensitivity of the study was 96.1%.
7. Specificity of the study was 95.65%.
8. Positive predictive value was 98.66%.
9. Negative Predictive value was 88%.

IV. INFERENCE AND CONCLUSION

Ultrasonography is a real time imaging technique without any hazards of ionization as with that of X-rays. It has high accuracy in diagnosis of acute appendicitis. It is a time saving and cost effective procedure. It is safe in pregnancy and can be also be used in bedside patients.

REFERENCES

- [1]. O'Connell P, Ronan "The Vermiform Appendix", Chapter 70 Bailey & Love's - Short Practice of Surgery, Arnold International Students Edition, 24th edition, London, 2004: 1203-1205.
- [2]. Deal DR "Acute appendicitis", Sleisenger MH, Fordtran JS (eds): *Gastrointestinal Disease - Pathophysiology, diagnosis and management*, Philadelphia, Saunders, 1973: 1494-1500.
- [3]. Cantrell JR, Stafford ES, The diminishing mortality from appendicitis, *Ann surgery*, 1955; 141: 749-758.
- [4]. Lewis FR, Holcroft JK, Boey J et al. Appendicitis - A critical review of diagnosis and treatment in 1000 cases, *Arch surgery* 1975; 110: 677-684.
- [5]. Puylaert JBCM. Acute appendicitis: Ultrasound evaluation using graded compression, *Radiology*, 1986; 158: 355-360.
- [6]. Birnbaum BA and Jeffrey RB. CT and Sonographic evaluation of acute right lower quadrant abdominal pain *Am J Roentgen*, 1998; 170:361-371.
- [7]. Berry J Jr., Malt RA. Appendicitis near its centenary. *Ann Surg* 1984; 200: 567-75.
- [8]. Simonovsky V: Sonographic detection of normal and abnormal appendix. *Clinical Radiology* 1999; 54: 533-9.
- [9]. Hoffman J, Rasmussen O. Aids in the diagnosis of acute appendicitis; *Br. J.Surg.* 1989; 76: 774-9.
- [10]. Gilmore OJA, Browett JP, Griffin PH et al. Appendicitis and mimicking conditions: a prospective study. *Lancet* 1975; 11:421-4.
- [11]. De Dombal FT, Leaper DJ, Horrocks JC et al : Human and computer - aided diagnosis of abdominal pain : further report with emphasis on performance of clinician. *Br. Med J* 1974; 1:376-80.