

Histologic Evaluation of Effect of *Xylopia Aethiopica* on Paracetamol Induced Renotoxicity.

Godwin Chinedu Uloneme
Department of Anatomy & Neurobiology,
Faculty of Basic Medical Sciences,
Imo State University, Owerri, Nigeria.

ABSTRACT

Objective: *Xylopia aethiopica*, known as 'uda' in the Igbo tribe of Nigeria, is a plant used in so many African countries for its perceived medicinal properties; this study therefore evaluated the histologic effect of extract of *xylopia aethiopica* on paracetamol induced renotoxicity in wister rats.

Materials and Methods: A total of 20 (10-12 month old) adult male wister rats were randomized in four separate cages labeled A, B, C and D, respectively with each cage containing five rats. The rats weighing between 200 and 230 grams were housed in the animal house of Anatomy and Neurobiology Department of faculty of Basic medical sciences, Imo state University, Owerri, where they were made to have free access to abundant feed and water amidst proper ventilation.

The group A rats which served as control were administered normal feed and water only, while group B was treated with 200mg/kg body weight of extract of *xylopia aethiopica* once daily (9am) for 14 days in addition to normal feed and water intake. Renotoxicity was induced in groups C and D rats by administering to them, 200mg/kg body weight of paracetamol once daily (9am) for 14 days. Group D rats were in addition, treated with 200mg/kg body weight of extract of *xylopia aethiopica* for 14 days (6pm daily). This was done same period the experimental rats (groups C and D) were administered 200mg/kg body weight of paracetamol, but in the evenings.

Results: The results showed that paracetamol administered to the experimental group C rats, induced renotoxicity that produced a damaging effect on the microanatomy of the kidney tissue as seen in Fig 3. On the other hand, the group D rats that received same treatment as group C, but were in addition administered 200mg/kg body weight of extract of *xylopia Aethiopica* presented anatomically normal kidney tissue that presented no easily noticeable histologic featural misrepresentations. The result obtained from group D photomicrograph was similar to that of group B photomicrograph administered 200mg/kg body weight of extract of *xylopia Aethiopica* only.

Conclusion: Extract of *xylopia Aethiopica* could be useful in the management of renotoxicity, and or possibly, other organ inflammatory conditions that could be associated with toxicity.

KEY WORDS: *Xylopia Aethiopica*, paracetamol, Renotoxicity, kidney, photomicrograph.

Date of Submission: 06-06-2021

Date of acceptance: 19-06-2021

I. INTRODUCTION

Xylopia Aethiopica is an aromatic evergreen plant that grows mainly in tropical Africa Orwa et al, (2009)^[1]. It belongs to the family *Annonaceae*, and it is called so many names that may have to do with where the plant is found; such as Guinea pepper, Senegal pepper, Negro pepper, West African pepper, etc. Joshi et al, (1997)^[2]. It is called 'Uda' in the Igbo tribe of Nigeria where this work is done. When the fruits are dried and crushed, a spicy aromatic semi powder is usually produced. The fruit in its different locally processed forms is being used in the treatment of stomachache, anaemia, dismanorrhoea, amenorrhoea, and even bronchitis Orwa et al, (2009)^[1]. In the Igbo tribe of Nigeria, it is used as a carminative and post-partum tonic aimed at alleviating after-birth wounds and as a lactating aid Maton, (1995)^[3]. In his work, Muanya (2008)^[4] stated that *xylopia Aethiopica* fruit has abortifacient properties. In the Southern African region, traditional birth attendants grind a mixture of the dried fruit of *xylopia Aethiopica* and dried leaves of *Rouwulfia Vomitaria* and administer it to pregnant woman at term to induce labour and achieve smooth delivery Gbile, (1989)^[5].

Onyebuagu et al (2014)^[6] believes that the fruit product could even be used to manage elevated blood cholesterol levels. Based on its wide use, and application in the treatment of so many diseases and ailments as stated above, the study seeks to unravel the effects (if any) of this wonderful plant fruit on the histology of a kidney inflicted with renotoxicity.

The kidney, being one of the most essential organs of the body that serves to filter blood in order to make urine, removes wastes, regulates ion concentrations, regulates fluid and electrolyte balance, produces hormones and enzymes, its overall well being should be ensured. But then, to determine whether extract of *xylopia aethiopica* could be of use in the treatment of a damaged kidney, especially when caused by renotoxicity, the condition (renotoxicity) has to be induced in wister rats using paracetamol, a drug that is most times used as analgesic and antipyretic Aghababian and Ahmed, (2010)^[7]. So as a drug of choice, paracetamol is commonly used for the relief of headaches, other minor aches and pains, and in combination with some opioid analgesics, it is used in the management of some severe conditions like post-surgical pain signh, (2008)^[8]. It has been shown that excess usage or overdose intake of paracetamol is a leading cause of poisoning worldwide Larson et al, (2005)^[9], as doses above 3 grams daily leads to toxicity of some organs, especially the kidney vuppalachiet et al, (2007)^[10]. From the foregoing, it could be understood that paracetamol could be used to induce renotoxicity for the purposes of this study.

II. MATERIALS AND METHODS

2.1 Materials used for the study:

The materials used for the study include twenty adult male wister rats, extract of *xylopia Aethiopica*, distilled water, Paracetamol, normal rat chow, 10% normal saline, solutions, tools and other laboratory devices required for hisological techniques.

2.2 Experimental Animals

Twenty adult male rats weighing between 200 and 230 grammes were used for the study that lasted for about thirty five days. The rats that aged between ten and twelve months were housed in the animal house of Anatomy and Neurobiology Department, Faculty of Basic Medical Sciences, Imo State University, Owerri. The rats were divided into four groups of five rats each and housed in four separate cages where they received sufficient water and were fed ad libitum with the normal rat chow for two weeks before experimentation commenced, and in the course of the experiment. The cages were then randomly labeled A, B, C, and D respectively and kept at a distance of about two metres from one another in the properly ventilated experimentation hall.

2.3 Preparation of xylopia Aethiopica powder

Air-dried fruits of *xylopia Aethiopica* were ground into fine powder using electric grinding device. Then using a suitable macerator, and rotator evaporator, resultant extract was obtained and preserved in the refrigerator.

2.4 Acute Toxicity Test (LD50) of paracetamol.

This exercise was carried out in two phases with a group of rats (similar in weight & age with experimental rats) isolated for the purpose. In the first phase, twelve adult male wister rats separated into three groups labeled 1,2 and 3, and containing four rats each were treated with varying doses of paracetamol, Group 1 received 10mg/kg body weight of paracetamol, group 2 received 50mg/kg body weight of paracetamol while group three was given 100mg/kg body weight of paracetamol.

The rats were then observed and monitored for about 24hours on a look out for strange behavioural manifestations or death. In the subsequent phase two, another group of twelve adult male wister rats placed under the same feeding and environmental conditions with the experimental rats were separated into three groups labeled 1b, 2b, 3b, and 4b, each containing three rats. Group 1b was treated with 200mg/kg body weight of paracetamol, group 2b received 300mg/kg body weight of paracetamol, while group 3b received as high as 400mg/kg body weight of the drug. Group 4b received the highest dose of 500mg/kg body weight of paracetamol and all the groups were observed and monitored for another 24 hours for strange or abnormal behavioural manifestations and susceptibility to death.

2.5 Treatment of the experimental rats

While the group A rats served as the control group and were treated with only distilled water, the group B rats were given 200mg/kg body weight of *xylopia Aethiopica* extract once daily (9am) for fourteen days. The group C rats received 200mg/kg body weight of paracetamol once daily (9am) also, while group D rats were administered 200mg/kg body weight of paracetamol once daily (9am) and then 200mg/kg body weight of *xylopia Aethiopica* extract also once daily, but by 6pm for fourteen days as well.

2.6 Collection of Sample:

At the end of the treatments, the different animal groups were sacrificed one after the other and the organ of interest, the kidney was harvested and preserved for histological processing and evaluation.

2.7 Histological processing

All the procedures and techniques employed in the tissue processing were carried out in the Histology laboratory of Anatomy Department where the prepared sections were evaluated under the microscope and photomicrographs taken for documentation and analysis.

III. RESULTS

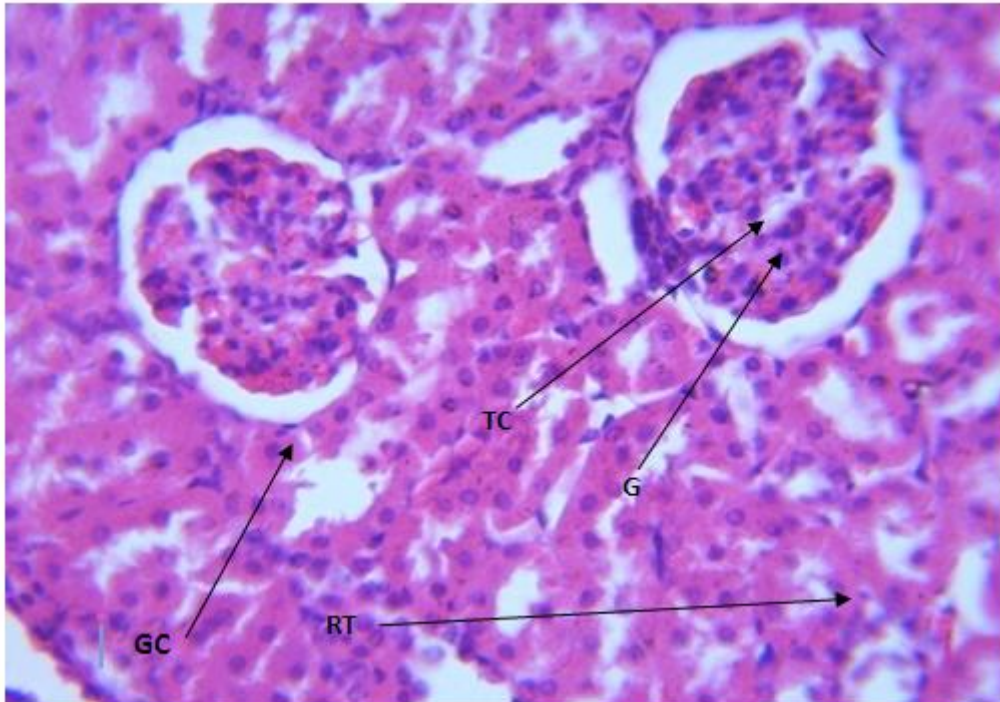


Fig 1. Photomicrograph representative of group A (control) section of kidney (H/E x400) shows normal renal structures; glomeruli (G), renal tubules(RT) , tubular cell (TC) bowman space (BS)

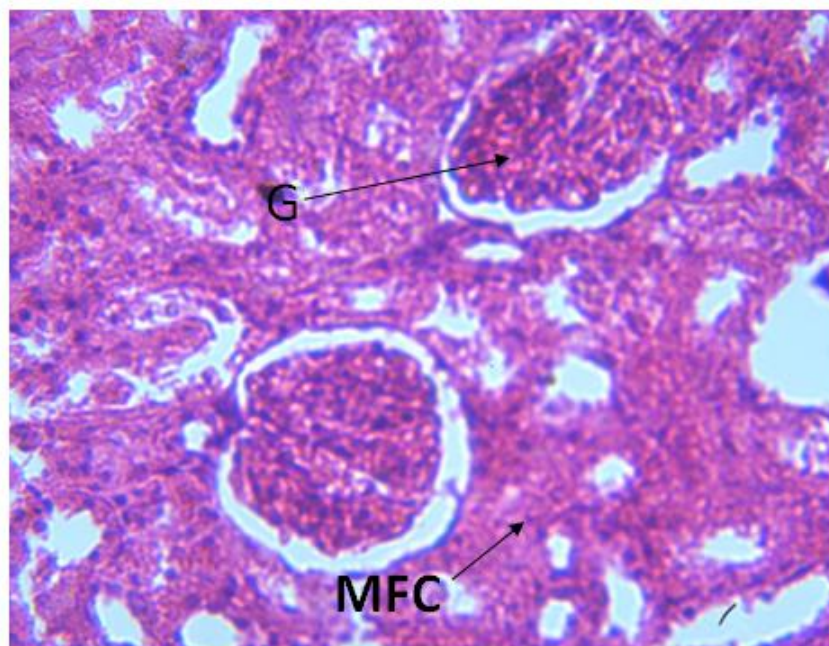


Fig 2. Photomicrograph representative of group B kidney administered only xylopia aethiopica (H/E x400) shows renal tissue with no easily noticeable histologic changes

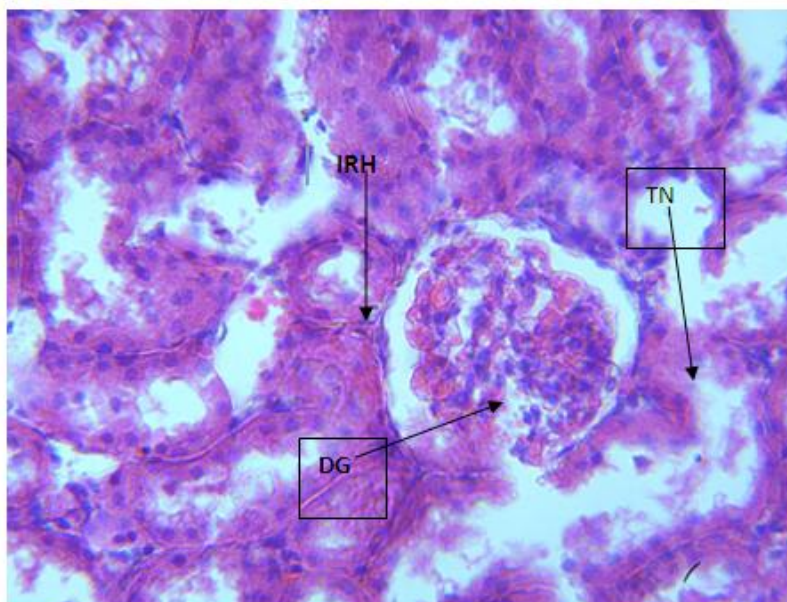


Fig 3. Photomicrograph representative of group C kidney treated with 200mg/kg body weight of Paracetamol (H/E x400) shows severely damaged renal tissue with tubular necrosis (TN), intra renal hemorrhage (IH), and degenerated glomeruli (DG).

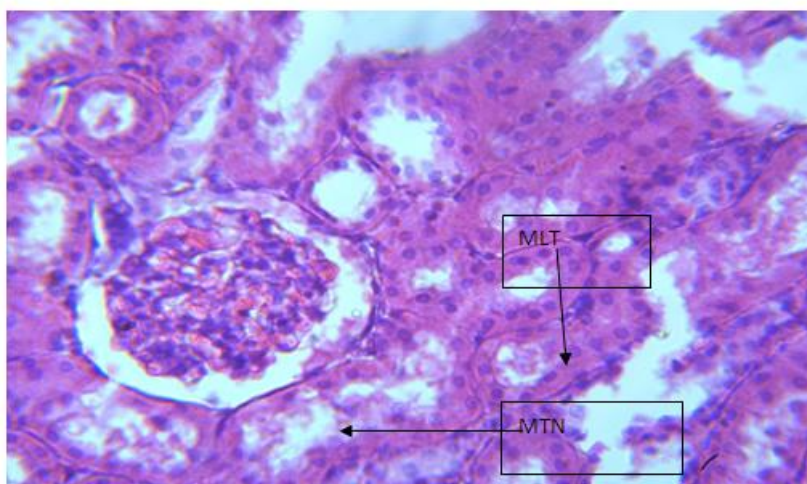


Fig 4. Photomicrograph representative of group D kidney treated with 200mg/kg body weight paracetamol and 200mg/kg body weight of xylopia aethiopica extract (H/E x400) showing mild to moderate healing on the renal tissue.

IV. DISCUSSION

The group A (control) rats photomicrograph representative of the kidney sections shows the renal corpuscles, the renal tubule system, the cortical nephrons and juxtamedullary nephrons visibly present.

In addition, the glomerulus formed by a network of capillaries from branches of the renal artery are observed presenting their normal histologic disposition. The photomicrograph representative of group B rats treated with only *xylopia Aethiopica* presents near normal histologic features very similar to those of the control (A) group.

The renal tissue has a very mild fatty tissue infiltration which in any way, did not affect the renal histologic architecture. So the renal corpuscles, the renal tubules system, the cortical and juxtamedullary nephrons and the glomerula all are intact. This result means that consumption of *xylopia Aethiopica* as a medicinal substance may not have a damaging effect on the kidney. The kidney tissue photomicrograph representative of group C rats treated with 200mg/kg body weight of paracetamol to induce renotoxicity shows a severely damaged kidney tissue. Renal haemorrhage associated with tubular necrosis and even renal tissue loss could be observed. This result means that the paracetamol administered to this group of rats actually induced renotoxicity in them. This is in agreement with the result of the acute toxicity test (LD50) of paracetamol done

on some separate group of rats in the course of this work where it was shown that paracetamol is capable of inducing renotoxicity, especially when abused.

In the case of the group D rats where 200mg/kg body weight of paracetamol was administered to them in the morning to possibly induce renotoxicity, and then given 200mg/kg body weight of extract of *Xylophia Aethiopica* in the evening, the renal tissue photomicrograph does not present any conspicuously distorted or damaged kidney microarchitectural system. Rather, a glomerular and renal tubular system in a seemingly recuperative state could be observed. It presents a clearly visible moderately healed tissue with a very mild tissue loss. Based on this result, it could be inferred that if the *xylophia Aethiopica* is administered to the group D rats for some more days, there might be complete healing and a possible return to a complete normal histologic architecture.

This means that the renotoxicity or damaging effect that may have been caused by the paracetamol was impeded and ameliorated by the *xylophia Aethiopica* extract administered to the rats some nine hours after paracetamol administration daily for fourteen days. From the foregoing, *xylophia aethiopica* fruit extract could be used to treat toxicity of the kidney and possibly, other body organs.

V. CONCLUSION

The drug, paracetamol or acetaminophen can actually be used to revive or heal renotoxicity or nephrotoxicity in the wister rats. But the fruit extract of the plant, *xylophia Aethiopica*, popularly known as 'Uda in Igbo tribe of Nigeria can be used to bring a healing effect on the damaged kidney tissue.

REFERENCES

- [1]. Orwa C., Mutua A., Kindt R., Jamnadass R., Anthony .S. (2009). "Xylophiaaethiopica" (PDF). *Agroforestry Database: a tree reference and selection guide version 4.0*. World Agroforestry Center.
- [2]. Joshi B., Lekhak S. and Sharma A. (2009). Antibacterial Property of Different Medicinal Plants: Ocimum sanctum, Cinnamomum zeylanicum, Xanthoxylum armatum and Origanum majorana. *Kathmandu University Journal of Science, Engineering and Technology*, 5(1): 143 – 150.
- [3]. Maton A., Hopkins J., McLaughlin C.W., Johnson S., Warner M.Q., David H. and Jill D.W. (1993). *Human Biology and Health*. Englewood Cliffs, New Jersey, USA: Prentice Hall.
- [4]. Muanya C. (2008). How Plants Can Induce Labour, Heal After-birth Wounds. *The Guardian Newspaper*.
- [5]. Gbile, Z.O. (1989). Ethnobotany, Taxonomy and Conservation of Medicinal Plants. *Forestry Research Institute of Nigeria, Ibadan*, pp14-17.
- [6]. Onyebuagu P.C., Aloamaka C.P. and Igweh, J.C. (2014). Xylophia Aethiopica Lower Plasma Lipid Precursors of Reproductive Hormones in Wistar Rats. *International Journal of Herbs and Pharm. Res.*; 2(4): 48-53.
- [7]. Aghababian, R. V. (2010). *Essentials of Emergency Medicine*. Jones & Bartlett Publishers. p. 814.
- [8]. Ahmad, J. (2010). *Hepatology and Transplant Hepatology: A Case Based Approach*. Springer. p.194.
- [9]. Singh Inderbir, (2011). "Textbook of Human Histology with color Atlas and Practical Guide". Jaypee Brothers Medical Publishers (P) LTD, Sixth edition.
- [10]. Larson A.M., Polson J., and Fontana R. J. (2005). "Acetaminophen-induced acute liver failure: results of a United States multicenter, prospective study". *Hepatology* 42 (6): 1364–72.
- [11]. Vuppalanchi R, Liangpunsakul S, Chalasani N (March 2007). "Etiology of new-onset jaundice: how often is it caused by idiosyncratic drug-induced liver injury in the United States?". *Am. J. Gastroenterol.* 102 (3): 558–62

Godwin Chinedu Uloneme. al. "Histologic Evaluation of Effect of Xylophia Aethiopica on Paracetamol Induced Renotoxicity." *International Journal of Pharmaceutical Science Invention*, vol. 10(05), 2021, pp 01-08. Journal DOI- 10.35629/6718